CLINICAL PRACTICE GUIDELINES

The American Society of Colon and Rectal Surgeons Clinical Practice Guidelines for the Management of Appendiceal Neoplasms

Wolfgang B. Gaertner, M.D., M.Sc., M.B.A.[1] • Shaun R. Brown, D.O.[2]
Michael Deutsch, M.D.[3] • Mehraneh D. Jafari, M.D.[4] • Mukta K. Krane, M.D.[5]
Vlad V. Simianu, M.D., M.P.H.[6] • Michael A. Valente, D.O.[7] • Amy L. Lightner, M.D.[8]
Daniel L. Feingold, M.D.[9] • Ian M. Paquette, M.D.[10]

On behalf of the Clinical Practice Guidelines Committee of the American Society of Colon and Rectal Surgeons
1 Division of Colon and Rectal Surgery, Department of Surgery, University of Minnesota, Minneapolis, Minnesota
2 Department of Surgery, Womack Army Medical Center, Vass, North Carolina
3 Division of Colon and Rectal Surgery, Department of Surgery, Penn State Health – Milton S. Hershey Medical Center, Hershey, Pennsylvania
4 Division of Colon and Rectal Surgery, Department of Surgery, Weill Cornell Medical College, New York, New York
5 Division of Colon and Rectal Surgery, Department of Surgery, University of Washington School of Medicine, Seattle, Washington
6 Division of Colon and Rectal Surgery, Department of Surgery, Virginia Mason Medical Center, Seattle, Washington
7 Division of Colon and Rectal Surgery, Department of Surgery, Cleveland Clinic, Cleveland, Ohio
8 Department of Surgery, Scripps Clinic, San Diego, California
9 Division of Colon and Rectal Surgery, Department of Surgery, Rutgers University, New Brunswick, New Jersey
10 Division of Colon and Rectal Surgery, Department of Surgery, University of Cincinnati, Cincinnati, Ohio

The American Society of Colon and Rectal Surgeons (ASCRS) is dedicated to ensuring high-quality patient care by advancing the science, prevention, and management of disorders and diseases of the colon, rectum, and anus. The Clinical Practice Guidelines Committee is composed of ASCRS members who are chosen because they have demonstrated expertise in the specialty of colon and rectal surgery. This committee was created to lead international efforts in defining quality care for conditions related to the colon, rectum, and anus and develop clinical practice guidelines based on the best available evidence. Although not proscriptive, these guidelines provide information on which decisions can be made and do not dictate a specific form of treatment. These guidelines are intended for use of all practitioners, health care workers, and patients who desire information regarding the management of the conditions addressed by the topics covered in these guidelines. These guidelines should not be deemed inclusive of all proper methods of care nor exclusive of methods of care reasonably directed toward obtaining the same results. The ultimate judgment regarding the propriety of any specific procedure must be made by the physician in light of all the circumstances presented by the individual patient.

CME Earn continuing medical education (CME) credit online at cme.lww.com. This activity has been approved for AMA PRA category 1 credit.

Funding/Support: None reported.

Financial Disclosure: Dr. Gaertner received proctor, speaker, and consultant fees from Intuitive Surgical; advisory board and consultant fees from Coloplast; consultant fees from Applied Medical; and advisory board, consultant, and speaker fees from BD. Dr. Jafari is member of the advisory board of Ethicon. Dr. Simianu received education fees and travel support from Intuitive Surgical; is member of the advisory board of BD; and received consultant fees from C-SATs. Dr. Lightner received consultant fees from Takeda Pharmaceuticals, Ossium Health, Mesoblast Ltd, and Boomerang Medical and is a chief medical officer at Direct Biologics.

Correspondence: Wolfgang B. Gaertner, M.D., M.Sc., 420 Delaware St. SE, MMC 450, University of Minnesota, Minneapolis, MN 55455. E-mail: gaert015@umn.edu

Dis Colon Rectum 2025; 68: 815–834
DOI: 10.1097/DCR.0000000000003796
© The ASCRS 2025

STATEMENT OF THE PROBLEM

Although relatively rare, the incidence of reported appendiceal neoplasms continues to rise globally.[1–4] During the past 3 decades, the incidence has increased from 0.12 cases to 1.9 per 1,000,000 person-years. This increase is occurring across all tumor subtypes, stages of disease, age groups, and sexes.[1] Between 2000 and 2016, there was a reported overall increase in the incidence of malignant appendiceal tumors by 232% in the United States and 292% in Canada.[5] The increase was noted for malignant adenocarcinomas and neuroendocrine appendiceal tumors in both countries, and the increase occurred across

Copyright © The American Society of Colon & Rectal Surgeons, Inc. Unauthorized reproduction of this article is prohibited.

all age groups, sexes, and stages of disease despite stable rates of appendectomy. The highest rate of increase was noted for appendiceal neuroendocrine malignant tumors diagnosed among the youngest age groups, specifically in those younger than 40 years.[5] It is unclear whether these observed increases reflect actual changes in the disease occurrence or simply greater recognition and reporting.

It is important for surgeons to be familiar with appendiceal pathology, as almost 350,000 appendectomies are performed annually in the United States, and neoplasia is found in approximately 1% to 2% of these specimens, with a concerning recent increase in malignant appendiceal tumors.[5–8] The management of these patients should involve use of a multidisciplinary team that includes pathologists familiar with appendiceal lesions and GI medical oncologists.

CLASSIFICATION BY HISTOPATHOLOGY

The terminology for appendiceal lesions has gone through numerous changes. To reduce confusion and provide consistency, unifying terminology was created and adopted by the World Health Organization (WHO) and the American Joint Committee on Cancer (AJCC) in 2010. In general terms, appendiceal neoplasms can be broadly described as epithelial, such as adenomas or adenocarcinomas, or nonepithelial (eg, neuroendocrine, lymphoma). The epithelial group may be further subdivided on the basis of mucin production given their distinctly different biologic behavior and oncologic outcomes from nonmucinous neoplasms.[6] The WHO classifies most noninvasive epithelial lesions as low-grade appendiceal mucinous neoplasms (LAMNs).[9,10] Histologically, LAMNs are characterized by the proliferation of low-grade mucinous epithelium into the layers of the appendix wall (lamina propria, submucosa, muscularis propria, subserosa) and can proliferate outside the appendix, resulting in peritoneal disease. This extra-appendiceal component can contain acellular or cellular mucin. The LAMN terminology includes lesions that were previously described as mucoceles or mucinous cystadenomas—terms no longer in use. The current AJCC version assigns LAMNs as pTis when it is confined to the submucosa or muscularis. T1 and T2 classifications are not applicable to LAMNs. If the mucinous neoplasm extends into the subserosa or serosa, it is classified as T3 or T4a, respectively. Based on WHO grading, LAMNs are grade 1 or well differentiated. High-grade appendiceal neoplasms (HAMNs) share some histologic features with LAMNs but exhibit more aggressive cytologic atypia without infiltrative invasion. Unlike LAMNs, they are classified as grade 2 or moderately differentiated. Based on molecular studies of HAMNs, these lesions contain mutations in *TP53*, *ATM*, and *APC*, which may be associated with greater atypia than seen with LAMNs.[11]

Appendiceal adenocarcinomas, unlike LAMNs and HAMNs, have infiltrative growth and may be either mucinous or nonmucinous. Mucinous adenocarcinomas are characterized by invasive glands containing high-grade cytologic atypia and extracellular mucin in more than 50% of the lesions.[9] Appendiceal adenocarcinomas resemble their colorectal counterparts histologically, regularly expressing p53, CD44, and CDX2, and are staged according to the TNM classification. When they contain signet-ring cells (more than 10%), they are classified as poorly differentiated and are prone to lymphatic spread. When more than 50% of signet-ring cells are present, they are classified as signet-ring cell adenocarcinoma.[6]

Goblet cell adenocarcinoma (GCA), previously referred to as goblet cell carcinoid (GCC), represents a variant of adenocarcinoma that demonstrates some features similar to a traditional neuroendocrine tumor (NET) with positive chromogranin A (CgA) staining.[9] However, these mixed neuroendocrine nonneuroendocrine neoplasms are more aggressive than traditional NETs and should be treated in a similar manner to classic appendiceal adenocarcinomas.[12,13] Others have suggested a broader classification of GCA as they have the potential to transform into signet-ring or poorly differentiated carcinomas: typical GCA, which refers to a well-differentiated GCA (group A); adenocarcinoma ex-GCC, which is further divided into signet-ring cell type (group B); and poorly differentiated adenocarcinoma type (group C).[14]

Appendiceal neoplasms may spread throughout the peritoneal cavity.[15] The most common route of metastasis is peritoneal invasion, with the ovaries and peritoneal surfaces most often involved. When this spread includes abundant mucin production within the peritoneal cavity, the term pseudomyxoma peritonei has been used. This is a clinical diagnosis and relies heavily on the histology of the peritoneal disease and not the primary tumor. Multiple classification systems have been used for the peritoneal component of the disease. The 2-tiered terminology was 1) low-grade mucinous carcinoma peritonei, previously called disseminated peritoneal adenomucinosis, and 2) high-grade mucinous carcinoma peritonei, previously called peritoneal mucinous carcinomatosis. In the current AJCC system, a 3-tiered classification system is used for mucinous and nonmucinous tumors: well differentiated (grade 1), moderately differentiated (grade 2), and poorly differentiated (grade 3). Because these tumors with peritoneal spread often recur after treatment and the 10-year overall survival rate after surgery is approximately 63%, they are considered malignant conditions[16–21] (Table 1).

Nonepithelial appendiceal neoplasms include NETs, previously known as carcinoid tumors. These lesions are histologically similar to NETs found elsewhere in the GI tract.[9] Appendiceal NETs are frequently asymptomatic and identified incidentally after routine appendectomy. Staging remains controversial and may be based on tumor

Copyright © The American Society of Colon & Rectal Surgeons, Inc. Unauthorized reproduction of this article is prohibited.

TABLE 1. Histologic classification of pseudomyxoma peritonei

Pathologic lesion	*Criteria*
Acellular mucin	• Mucin within peritoneal cavity without neoplastic epithelial cells
Low-grade mucinous carcinoma peritonei (DPAM)	• Epithelial component typically scanty • Minimal cytological atypia • Strips, gland-like structures, or small cell clusters
High-grade mucinous carcinoma peritonei (PMCA)	• Relatively more cellular • Cribriform growth pattern • High-grade cytological atypia • Numerous mitoses
High-grade mucinous carcinoma peritonei with signet-rings cells (PMCA-S)	• Any lesion with a signet-ring cell component, that is, round cells with intracytoplasmic mucin pushing nucleus against cell membrane

Adapted from Carr et al.[11]
DPAM = disseminated peritoneal adenomucinosis; PMCA = peritoneal mucinous carcinomatosis; PMCA-S = peritoneal mucinous carcinomatosis with signet-ring cells.

size, depth of invasion, or degree of differentiation. Other rare nonepithelial appendiceal neoplasms include GI stromal tumors, lymphomas, and neural proliferations, which are outside the scope of this guideline.

METHODOLOGY

These guidelines were built on the previous clinical practice guidelines for the management of appendiceal neoplasms published in 2019.[22] An organized search of MEDLINE, PubMed, Embase, and the Cochrane Database of Systematic Reviews was performed from December 1, 2018, through February 6, 2025. Pertinent inclusion criteria were English language article and adult human patients, and both current and archaic terminology for appendiceal neoplasms were included as follows: (appendiceal, appendix, appendicular) AND (adenocarcinoma, carcinoma, mucinous, pseudomyxoma, signet, cystadenoma, tumor, tumour, neoplasm, cancer). These groups were combined with various treatment modalities to include surgery and chemotherapy. Directed searches using embedded references from primary articles were performed in selected circumstances. Of 1261 records screened, 347 were evaluated for their level of evidence, favoring clinical trials, meta-analyses/systematic reviews, comparative studies, and large registry retrospective studies over single institutional series, retrospective reviews, and peer-reviewed observational studies. Additional references identified through embedded references and other sources as well as practice guidelines and consensus statements from relevant societies were also reviewed. A final list of 72 sources was evaluated for methodological quality, the evidence base was examined, and a treatment guideline was formulated by the subcommittee for this guideline (Fig. 1).

Certainty of Evidence

The final grade of recommendation and level of evidence for each statement were determined using the Grades of Recommendation, Assessment, Development, and Evaluation (GRADE) methodology system. The certainty of evidence reflects the extent of our confidence in the estimates of effect. Evidence from randomized controlled trials start as high certainty, and evidence derived from observational studies start as low certainty. For each outcome, the evidence is graded as high, moderate, low, or very low (Table 2). The evidence can be rated down for risk of bias, inconsistency, indirectness, imprecision, and publication bias. The certainty of evidence originating from observational studies can be rated up when there is a large magnitude of effect or dose–response relationship. As per GRADE methodology, recommendations are labeled as "strong" or "conditional." All statements with strength of GRADE recommendations are stated in Table 3. Table 4 summarizes the new, updated, and excluded recommended clinical practice guidelines compared with the 2019 guidelines. Recommendations formulated by the subcommittee were reviewed by the entire Clinical Practice Guidelines Committee. The submission was then approved by the ASCRS Executive Council and peer-reviewed in *Diseases of the Colon & Rectum*. In general, each ASCRS Clinical Practice Guideline is updated approximately every 5 years. No funding was received for preparing this guideline, and the authors have declared no competing interests related to this material. This guideline conforms to the Appraisal of Guidelines for Research and Evaluation checklist.[23]

GENERAL CONSIDERATIONS

1. **Colonoscopy should be performed in patients with confirmed or suspected appendiceal neoplasms. Strength of recommendation: strong recommendation based on low-quality evidence.**

Patients with appendiceal neoplasms have been reported to be at an increased risk of synchronous colonic lesions compared with the general population. Population-based studies have reported that 13% to 42% of patients with primary appendiceal lesions have concurrent colorectal neoplasia.[7,8,24,25] In a population-based study from the Netherlands from 1995 to 2005, which included 1482 patients with an appendiceal epithelial neoplasm, 193 patients (13%) had an

Copyright © The American Society of Colon & Rectal Surgeons, Inc. Unauthorized reproduction of this article is prohibited.

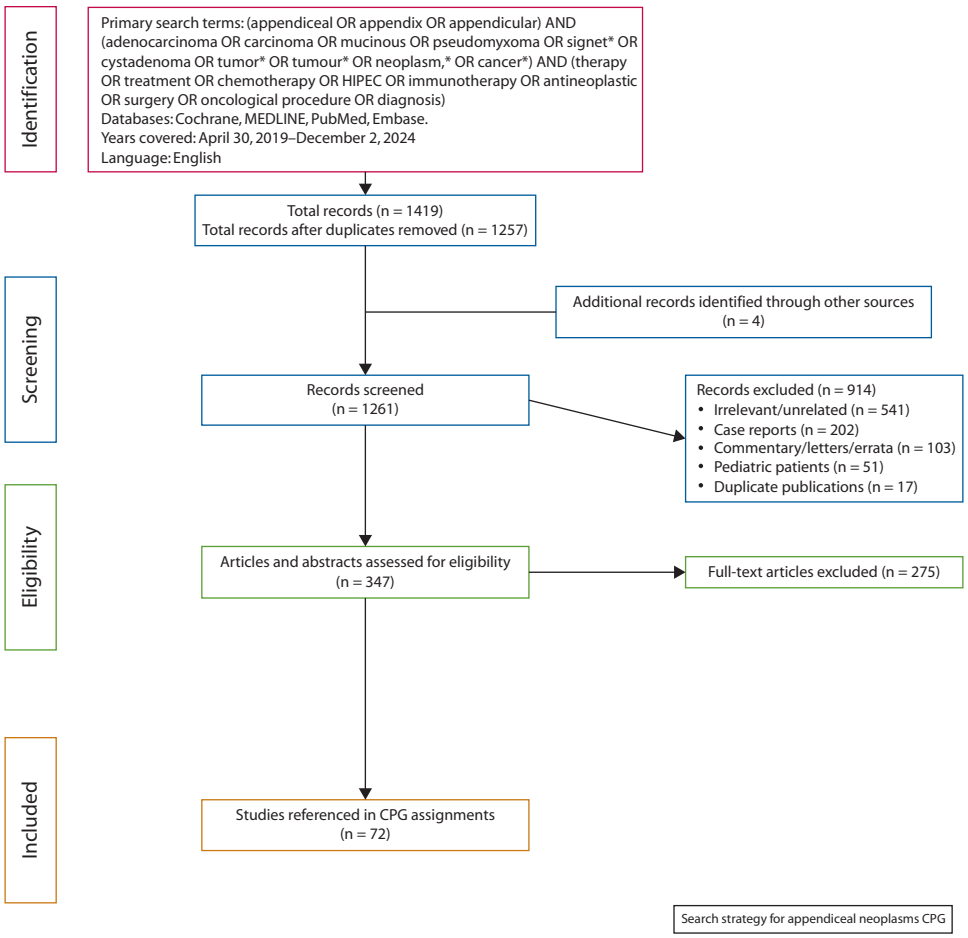

FIGURE 1. Preferred Reporting Items for Systematic Reviews and Meta-Analyses diagram. CPG = clinical practice guidelines; HIPEC = hyperthermic intraperitoneal chemotherapy.

TABLE 2. Interpretation of strong and conditional recommendations using the GRADE approach

Evaluation	*Description*
Recommendation	
Strong	Most individuals should receive the intervention. Formal decision aids are not likely to be needed to help individuals make decisions consistent with their values and preferences
Conditional	Different choices will be appropriate for individual patients consistent with their values and preferences. Use shared decision-making. Decision aids may be useful in helping patients make decisions consistent with their individual risks, values, and preferences
GRADE certainty ranking	
High	The authors are confident that the true effect is similar to the estimated effect
Moderate	The authors believe that the true effect is probably close to the estimated effect
Low	The true effect might be markedly different from the estimated effect
Very low	The true effect is probably markedly different from the estimated effect

GRADE = Grading of Recommendations, Assessments, Development, and Evaluation.

incidental colonic adenoma (n = 37) or adenocarcinoma (n = 156).[7] In this study, the primary pathology of the appendiceal neoplasms was reported as mucinous cystadenoma (32%), LAMN (31%), and nonmucinous adenoma (26%). Of note, the majority (82%) of colonic adenocarcinomas discovered were right sided. Given the risk of synchronous colonic lesions, patients with a suspected appendiceal neoplasm on imaging should undergo a preoperative colonoscopy before formal resection of the appendiceal neoplasm.

2. **Appendectomy should be performed if a grossly abnormal appendix is encountered during an unrelated abdominal operation. Strength of recommendation: strong recommendation based on low-quality evidence.**

Copyright © The American Society of Colon & Rectal Surgeons, Inc. Unauthorized reproduction of this article is prohibited.

TABLE 3. Summary and strength of GRADE recommendations

	Summary	*Recommendation strength*	*GRADE quality of evidence*
1	Colonoscopy should be performed in patients with confirmed or suspected appendiceal neoplasms	Strong	Low
2	Appendectomy should be performed if a grossly abnormal appendix is encountered during an unrelated abdominal operation	Strong	Low
3	Interval appendectomy after complicated appendicitis is typically recommended in adult patients older than 40 y and in those with imaging findings suggestive of a malignant process, given the risk of occult malignancy	Conditional	Low
4	Preoperative assessment of patients with appendiceal NETs should include physical examination, colonoscopy, and CT or MRI of the chest, abdomen, and pelvis	Strong	Low
5	NET-specific imaging should be considered in patients with lesions >2 cm, symptoms of carcinoid syndrome, and findings indeterminate for metastatic disease in other imaging studies	Conditional	Moderate
6	Biochemical testing should not be routinely performed in patients with appendiceal NETs before treatment, although in the setting of metastatic disease, it may be considered to establish a baseline for future disease monitoring	Strong	Moderate
7	Extent of surgical resection of appendiceal NETs is determined by tumor size and histologic features	Strong	Low
8	Surveillance after resection of appendiceal NETs with curative intent should selectively involve physical examination, serial biochemical testing, and imaging of the chest, abdomen, and pelvis using either CT or MRI	Conditional	Low
9	CEA, CA 19-9, and CA-125 should typically be assessed on the diagnosis of appendiceal epithelial neoplasms and routinely surveyed after resection	Conditional	Low
10	Cross-sectional imaging with CT or MRI should be obtained at the time of diagnosis in patients with appendiceal epithelial neoplasms and routinely used for postoperative surveillance	Strong	Moderate
11	Routine peritoneal cytology is not recommended in patients with appendiceal tumors	Conditional	Low
12	Patients with LAMNs with negative margins and no evidence of perforation or peritoneal involvement are safely treated with appendectomy alone	Strong	Moderate
13	Patients with nonmetastatic adenocarcinoma of the appendix should undergo right hemicolectomy. However, in the setting of peritoneal spread, right hemicolectomy typically does not confer a survival benefit	Strong	Low
14	Cytoreductive surgery is indicated in select patients with appendiceal neoplasms and evidence of peritoneal involvement	Strong	Moderate
15	In patients with appendiceal epithelial neoplasms, intraperitoneal chemotherapy after cytoreductive surgery compared to cytoreductive surgery alone may reduce peritoneal disease recurrence, although its impact on overall survival is not established and has been associated with increased costs and toxicity	Strong	Moderate
16	Systemic chemotherapy may improve survival in patients with metastatic, lymph node positive, HAMNs, and adenocarcinoma with peritoneal metastases. Routine use of systemic chemotherapy for LAMNs or well-differentiated mucinous adenocarcinoma with peritoneal spread is not recommended	Strong	Low
17	Minimally invasive aerosolized approaches to peritoneal carcinomatosis require specialized equipment and expertise and have shown acceptable short-term oncologic outcomes, but there is a paucity of long-term data	Conditional	Low

CA-125 = cancer antigen 125; CA 19-9 = carbohydrate antigen 19-9; GRADE = Grades of Recommendation, Assessment, Development, and Evaluation; HAMN = high-grade appendiceal neoplasm; LAMN = low-grade appendiceal neoplasm; NET = traditional neuroendocrine tumor.

During an abdominal or pelvic operation unrelated to appendiceal pathology, an appendectomy is warranted for incidental findings of luminal dilation, serosal irregularity, or mass. Care must be taken to avoid intraoperative perforation and spillage.[26–28] In most cases, an appendectomy or partial cecectomy is sufficient when an abnormal appendix is encountered incidentally. The extent of resection is predominantly based on the involvement of the base of the appendix with the priority of obtaining a grossly negative margin, and care should be taken to avoid rupture, regardless of the operative approach.[29] When performing a minimally invasive approach, surgeons should use a specimen retrieval bag to avoid spilling mucin in the peritoneal cavity or abdominal wall. Intraperitoneal mucin found incidentally may suggest the presence of a mucinous neoplasm of the GI or gynecologic tracts. In this setting, careful inspection and documentation of the appendix, adnexa in a female patient, and entire extent of peritoneal disease using the peritoneal cancer index (PCI) scoring system (see the following paragraphs for details), including representative biopsies, is warranted. In addition, in the presence of peritoneal disease or when the neoplasm is not confined to the appendix, representative biopsies without appendectomy are recommended. Data from multiple retrospective, single-institution studies do not support routine appendectomy for a normal-appearing appendix in the setting of an ovarian mucinous neoplasm because the incidence of synchronous appendiceal pathology in these cases is low.[30–32]

Although helpful with other GI malignancies and peritoneal implants, the intraoperative frozen section of

Copyright © The American Society of Colon & Rectal Surgeons, Inc. Unauthorized reproduction of this article is prohibited.

TABLE 4. What is new in the 2025 ASCRS clinical practice guidelines on the management of appendiceal neoplasms

2025 New recommendations
3. Interval appendectomy after complicated appendicitis is typically recommended in adult patients older than 40 years and in those with imaging findings suggestive of a malignant process, given the risk of occult malignancy. Strength of recommendation: conditional recommendation based on low-quality evidence
17. Minimally invasive aerosolized approaches to peritoneal carcinomatosis require specialized equipment and expertise and have shown acceptable short-term oncologic outcomes, but there is a paucity of long-term data. Strength of recommendation: conditional recommendation based on low-quality evidence
2019 Updated recommendations
6. Biochemical testing should not be routinely performed in patients with appendiceal NETs before treatment, although in the setting of metastatic disease, it may be considered to establish a baseline for future disease monitoring. Strength of recommendation: strong recommendation based on moderate-quality evidence (previous recommendation stated routine biochemical testing)
10. Cross-sectional imaging with CT or MRI should be obtained at the time of diagnosis in patients with appendiceal epithelial neoplasms and routinely used for postoperative surveillance. Strength of recommendation: strong recommendation based on moderate-quality evidence (previously strong recommendation based on low-quality evidence)
2019 Excluded recommendations
1. Patients with appendiceal neoplasms should undergo a complete history and physical examination. Strength of recommendation: strong recommendation based on low-quality evidence

ASCRS = American Society of Colon and Rectal Surgeons; NET = traditional neuroendocrine tumor.

appendiceal neoplasms often provides inaccurate results, especially with mucinous neoplasms.[9–11] A final definitive diagnosis usually requires analysis of the entire specimen and should be reviewed before assessing the patient's candidacy for an oncologic right colectomy.

3. Interval appendectomy after complicated appendicitis is typically recommended in adult patients older than age 40 years and in those with imaging findings suggestive of a malignant process, given the risk of occult malignancy. Strength of recommendation: conditional recommendation based on low-quality evidence.

The low rate of recurrent appendicitis after initial nonsurgical management of complicated appendicitis supports the recently implemented strategy of omitting routine interval appendectomy. Arguments against routine interval appendectomy include cost, potential morbidity, complications associated with the procedure, low rate of recurrence after treatment with antibiotics (5%–18%), and a historically low incidence of appendiceal neoplasms in patients with acute appendicitis (1%–2%).[33–39] However, reports on the incidence of appendiceal neoplasms were largely from retrospective studies with significant heterogeneity, lack of axial imaging, and a substantial number of pediatric patients.[7,36,40] Several recent reports have suggested an increased incidence of appendiceal neoplasms in adult patients with acute appendicitis (20%–29%).[41–43] Reported risk factors for appendiceal neoplasms after acute appendicitis include complicated appendicitis, age older than 40 years, and radiologic appearance of an inflammatory mass.[35,43–45]

A retrospective study of 402 patients who underwent an interval appendectomy for complicated appendicitis showed an overall neoplasm rate of 9%. Patients with an appendiceal neoplasm were significantly older (56.6 vs 45.1 years, $p < 0.01$).[43] No patients younger than 30 years had a neoplasm. The rate of appendiceal neoplasms was 11% in patients 30 years or older, 16% in those older than 50 years, and 43% in those older than 80 years.[43] A systematic review and meta-analysis of 8 studies showed a pooled prevalence of neoplasms after interval appendectomy of 11% (95% CI, 7–15; $I^2 = 37.5\%$, $p = 0.13$).[45] Among these patients, appendiceal mucinous neoplasms occurred in 43% (95% CI, 19–68), adenocarcinoma in 29% (95% CI, 6–51), appendiceal neuroendocrine neoplasm in 21% (95% CI, 6–36), GCA in 13% (95% CI, 2–28), and adenoma or serrated lesions in 20% (95% CI, 0–41) of cases.[45]

The decision-making for performing an interval appendectomy after initial nonoperative management of presumed appendicitis is complex. Surgeons must consider the risk for occult appendiceal neoplasm, and at a minimum, patients should be informed of this risk and educated on their potential pathological diagnoses.

APPENDICEAL NETS

4. Preoperative assessment of patients with appendiceal NETs should include physical examination, colonoscopy, and CT or MRI of the chest, abdomen, and pelvis. Strength of recommendation: strong recommendation based on low-quality evidence.

Preoperative evaluation of patients with appendiceal NETs should include a history and physical examination with an associated review of systems. Although rare with appendiceal NETs, positive review of systems for carcinoid syndrome features (eg, flushing, diarrhea) may indicate the presence of metastatic disease or synchronous lesions, potentially altering the therapeutic approach.[46,47] In comparison to small-bowel NETs, appendiceal NETs rarely have synchronous lesions or distant metastatic disease.[48]

Copyright © The American Society of Colon & Rectal Surgeons, Inc. Unauthorized reproduction of this article is prohibited.

A preoperative colonoscopy is indicated, given the association with synchronous, non-NET lesions that may be present up to 22% of the time.[49–53] Additional findings on screening colonoscopy also may inform surgical planning.

Additionally, preoperative imaging is important for adequate staging, mainly to rule out distant metastatic disease. CT and ultrasound imaging have been associated with inferior results in general compared with intraoperative findings and final surgical pathology results, with accuracy rates of 40% and 25.5%, respectively.[54] MRI has been associated with improved staging, operative planning, and outcomes.[47,55] NET-specific imaging is discussed in the next statement.

5. NET-specific imaging should be considered in patients with lesions >2 cm, symptoms of carcinoid syndrome, and findings indeterminate for metastatic disease on other imaging studies. Strength of recommendation: conditional recommendation based on moderate-quality evidence.

Appendiceal NETs typically express somatostatin receptors, making imaging studies using radiolabeled somatostatin analogs, including ^{68}Ga-DOTATATE, highly useful in disease detection. Previously, somatostatin receptor scintigraphy (SSRS) was the mainstay of NET imaging, but it has been largely replaced by ^{68}Ga-DOTA PET/CT scans.[56] ^{68}Ga-DOTA PET/CT is more sensitive for the detection of well-differentiated NET tumors than SSRS and may also detect occult lesions.[57,58] In a prospective study of 101 consecutive patients with NETs, of whom 75% had gastroenteropancreatic NETs, ^{68}Ga-DOTA PET/CT identified additional metastatic lesions in 48% of patients (37/77) with known metastatic disease and in 21% of patients (5/24) without known metastatic disease compared with prior cross-sectional imaging with CT/MRI and/or indium-111 pentetreotide.[59] In addition, a previously occult primary tumor was detected in 23% of patients (3/13) with primary unknown metastatic disease. Treatment plans were modified in 35% of patients (36/101) based on the results of the ^{68}Ga-DOTA PET/CT.[59] In addition to higher diagnostic accuracy, ^{68}Ga-DOTA PET/CT scans also require less time and a lower dose of radiation per scan compared with SSRS.

^{68}Ga-DOTA PET/CT has also been shown to be superior to FDG F18 PET/CT in the detection of gastroenteropancreatic NETs.[60–62] Given the high sensitivity of ^{68}Ga-DOTA PET/CT, this additional information may also help guide surgical management and the selection of somatostatin receptor antagonists in the setting of locoregionally advanced and metastatic disease.[63,64] However, the utility of DOTA scans should be balanced with the cost of the study. ^{68}Ga-DOTA PET/CT scans should predominately be considered in cases where there is higher potential for metastatic disease, including lesions >2 cm, symptoms of carcinoid syndrome, and findings indeterminate for metastatic disease on other imaging studies.[63,64]

6. Biochemical testing should not be routinely performed in patients with appendiceal NETs before treatment, although in the setting of metastatic disease, it may be considered to establish a baseline for future disease monitoring. Strength of recommendation: strong recommendation based on moderate-quality evidence.

Appendiceal NETs are generally not biochemically active unless there is a significant burden of hepatic metastases or there is direct systemic venous drainage leading to first-pass metabolism. Serum CgA and 24-hour urine 5-hydroxyindoleacetic acid (5-HIAA) are the most common metabolites produced by NETs; however, given their poor sensitivity and specificity in detecting early metastatic disease, these markers should not be routinely checked at initial diagnosis of appendiceal NETs.[65,66] Baseline values may be selectively performed in patients with radiographic evidence of metastatic disease, mainly for disease monitoring and assessment of treatment response.[67] Although mainly investigational, a multianalyte liquid biopsy of NET gene expression in blood recently showed increased diagnostic utility of early metastatic disease in GI NETs compared with CgA.[68–70]

7. Extent of surgical resection of appendiceal NETs is determined by tumor size and histologic features. Strength of recommendation: strong recommendation based on low-quality evidence.

For nonmetastatic NETs confined to the appendix, treatment is generally based on size and histopathology of the primary tumor. Tumors of size >2 cm warrant a right hemicolectomy because nodal metastases are present in up to 40% of patients.[71–74] However, controversy remains in the surgical management of appendiceal NETs measuring 1 to 2 cm in size.[71,72,75] A large series of 435 patients showed that a cutoff tumor size >1.5 cm was independently related to nodal metastases.[76] In addition to size, tumor location at the base of the appendix, grading G2, and mesoappendiceal or lymphovascular invasion are also associated with nodal invasion.[47,77,78] Lymphovascular invasion has also been shown to be an independent risk factor for metastasis in patients with tumors <2 cm.[77,79,80] Additional unfavorable findings on histology include mesoappendiceal invasion >3 mm, advanced grade consisting of elevated mitotic index (more than 2 mitoses per high-power field), GCC histology, and Ki-67 index of more than 3% (Fig. 2).[73,77,81] Decision-making for right hemicolectomy in small- and intermediate-sized appendiceal NETs should be made on an individual basis, with consideration given to histologic features and patient comorbidities and preferences, in a multidisciplinary setting.[77] Although the majority of appendiceal NETs occur at the tip of the appendix,

Copyright © The American Society of Colon & Rectal Surgeons, Inc. Unauthorized reproduction of this article is prohibited.

patients with tumors present at the base of the appendix or those who have undergone resection with a positive margin should typically undergo right hemicolectomy with regional lymphadenectomy.[82] Lesions <1 cm in diameter and without unfavorable features are adequately treated with an appendectomy and removal of the entire mesoappendix. Long-term disease-free survival in these patients is 100%.[83–86]

8. Surveillance after resection of appendiceal NETs with curative intent should selectively involve physical examination, serial biochemical testing, and imaging of the chest, abdomen, and pelvis using either CT or MRI. Strength of recommendation: conditional recommendation based on low-quality evidence.

Surveillance after curative intent resection of appendiceal NETs depends on tumor size and histologic features. Overall and disease-free 5-year survival rates are very high, ranging from 85% to 95%,[80–89] and the overall risk of metastases is approximately 10%.[90,91] Small (<1 cm) lesions with favorable histologic features may not need surveillance. For lesions >2 cm or those with more aggressive histopathologic features, surveillance should typically include an updated history and physical examination, cross-sectional imaging, and colonoscopy. Typical intervals between surveillance evaluations are every 6 to 12 months for a total of 5 to 10 years,[92] depending on tumor grade and stage, as well as the patient's clinical course.[91] Given that many NETs are removed during appendectomy for appendicitis,[47] patients should undergo colonoscopy after removal to rule out synchronous lesions. If a colonoscopy was performed before appendectomy, standard guidelines should be used during follow-up.

Appendiceal NETs are generally not biochemically active unless there is a significant burden of hepatic metastases or they have direct systemic venous drainage leading to first-pass metabolism, in which case the serum tumor markers CgA and 5-HIAA may help detect disease recurrence and response to therapy. In one meta-analysis including all types of GI NETs, CgA showed a sensitivity and specificity for disease progression or recurrence of 46% to 100% and 68% to 90%, respectively.[93] CgA and urine 5-HIAA levels are more sensible in those cases where the initial values were elevated. However, because of the nonspecific nature of these biomarkers, correlation with imaging studies is recommended.[94]

Currently, there are insufficient data to support the routine use of NET-specific imaging modalities for routine surveillance, although they may be beneficial in confirming recurrent disease discovered on CT or MRI.[68,95,96] Ga-DOTA imaging is useful for restaging when there is clinical or biochemical evidence of disease recurrence or progression despite negative conventional imaging.[97]

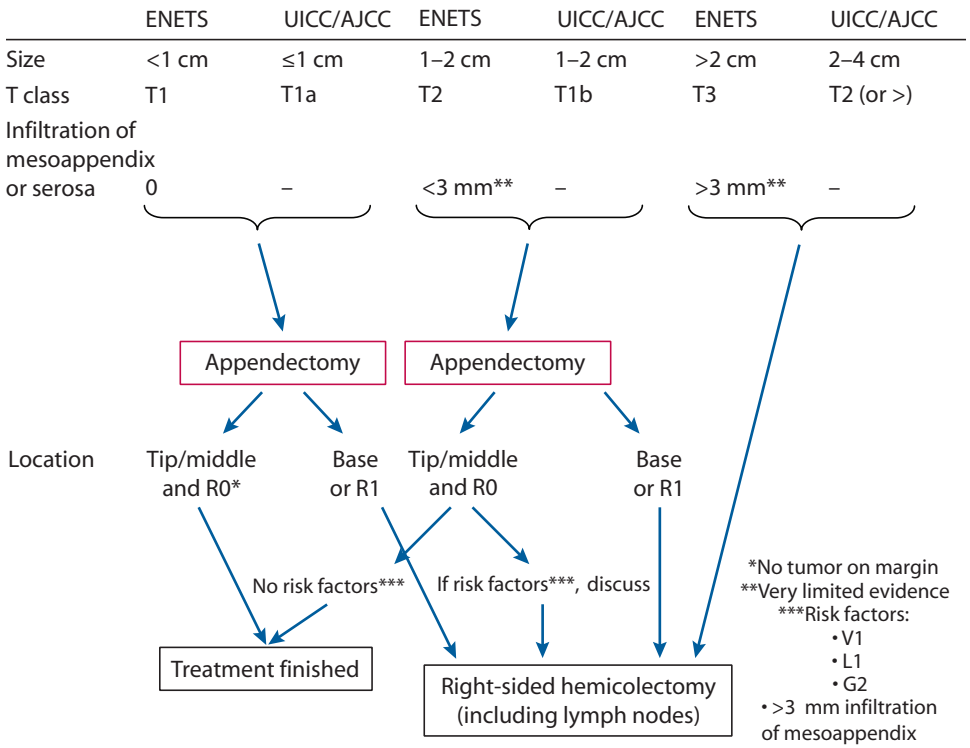

FIGURE 2. Therapeutic algorithm for small appendiceal NET. AJCC = American Joint Committee on Cancer; ENET = European Neuroendocrine Tumor Society; G2 = grade 2 tumor (Ki-67 3%–20%); L1 = lymphatic invasion; NET = neuroendocrine tumor; UICC = Union for International Cancer Control; V1 = vascular invasion.

Copyright © The American Society of Colon & Rectal Surgeons, Inc. Unauthorized reproduction of this article is prohibited.

APPENDICEAL MUCINOUS NEOPLASM AND ADENOCARCINOMA

9. CEA, CA 19-9, and CA-125 should typically be assessed on diagnosis of appendiceal epithelial neoplasms and routinely surveyed after resection. Strength of recommendation: conditional recommendation based on low-quality evidence.

The serum tumor markers CEA, CA 19-9, and CA-125 are frequently obtained on diagnosis of appendiceal mucinous neoplasms and routinely monitored to assess disease remission or progression.[98] Although their individual predictability of disease recurrence has not been well characterized, combining tumor markers with imaging at baseline, during chemotherapy, and postoperatively has been useful in evaluating response to therapy and monitoring for disease recurrence. In the setting of mucinous adenocarcinoma of the appendix, a normal baseline CA-125 has been shown to correlate with achieving complete cytoreduction.[99] Elevated baseline CA19-9 has also been described as an independent predictor of worse progression-free survival and can be useful to diagnose disease recurrence after cytoreductive surgery (CRS) and hyperthermic intraperitoneal chemotherapy (HIPEC).[99–101]

The ultrasound HIPEC collaborative demonstrated worse progression-free survival in patients with elevated preoperative CA19-9 and worse overall survival in patients with mucinous adenocarcinoma and elevated CEA after CRS and HIPEC.[102] However, surveillance cross-sectional imaging is more sensitive for detecting peritoneal disease recurrence than tumor markers alone.[103] Despite many investigational attempts to use molecular profiling and tumor markers to distinguish LAMNs versus HAMNs, the most important diagnostic component is having an experienced pathologist who is familiar with this disease process review the pathology.[104–107]

The sensitivity of cell-free circulating tumor DNA (ctDNA) in patients with appendiceal neoplasms has been reported as lower compared with other metastatic GI tumors.[108] However, the presence of ctDNA in both plasma and peritoneal fluid has been shown to be associated with systemic and peritoneal recurrence.[109]

10. Cross-sectional imaging with CT or MRI should be obtained at the time of diagnosis in patients with appendiceal epithelial neoplasms and routinely used for postoperative surveillance. Strength of recommendation: strong recommendation based on moderate-quality evidence.

CT of the chest, abdomen, and pelvis is the most common imaging modality used to evaluate the primary tumor and assess for metastatic disease. The addition of a PET scan has not been shown to improve staging or significantly change management.[110] MRI can detect extraluminal mucin and has also been shown to be superior to CT in the detection of peritoneal disease using a combination of diffusion-weighted imaging and gadolinium-enhanced sequences.[111] In small noncomparison studies, MRI has proven useful in predicting preoperative PCI and may be used in postoperative surveillance after CRS and HIPEC.[98,106] Unfortunately, cross-sectional imaging is inaccurate for obtaining a preoperative diagnosis and often will miss peritoneal disease. When a peritoneal disease is seen on imaging, several scoring systems have been developed to predict the likelihood of obtaining complete cytoreduction.[112] Although some have proposed using the 2010 WHO pathologic classification as a framework to report imaging findings in patients with appendiceal neoplasms, no structured imaging reporting systems are routinely used in this patient population.[113]

Patients with LAMNs and HAMNs who undergo a margin-negative appendectomy with disease confined to the appendix rarely develop pseudomyxoma peritonei; therefore, frequent postoperative imaging for extended intervals is typical of minimal benefit.[8,114–116] Postoperative surveillance must be individualized according to tumor and patient characteristics. Patients with high-grade tumors or who undergo right hemicolectomy because of a locally advanced or perforated tumor, who have indeterminate surgical margins, or who had lymphatic or peritoneal disease should typically undergo CT or MRI every 6 months for the first 3 years and yearly thereafter for 5 to 10 years. In patients with acellular or low-grade peritoneal disease who have undergone CRS and HIPEC, CT or MRI of the abdomen and pelvis is recommended at 3 to 6 months postoperatively (baseline), then every 6 to 12 months with tumor markers during the first 3 years and annual surveillance thereafter.[116–120]

11. Routine peritoneal cytology is not recommended in patients with appendiceal tumors. Strength of recommendation: conditional recommendation based on low-quality evidence.

Although positive peritoneal cytology has varying degrees of utility in patients with pancreatic, gastric, or ovarian malignancies, the use of cytology in patients with appendiceal neoplasms remains unknown.[121–123] Some insight may be gained from extrapolation of studies on colorectal cancer with peritoneal spread. Positive peritoneal cytology occurs in 23.5% of treated patients and correlates with overall survival (19 vs 44 months for negative peritoneal cytology; $p = 0.01$).[124] Another study of 205 patients with colorectal cancer undergoing CRS and HIPEC also showed that positive peritoneal cytology was independently associated with worse progression-free survival.[125] Neither of these studies performed a subgroup analysis for patients with appendiceal malignancies or evaluated its role in the decision to perform HIPEC.

Copyright © The American Society of Colon & Rectal Surgeons, Inc. Unauthorized reproduction of this article is prohibited.

During the past decade, various liquid biopsy techniques have emerged as viable alternatives to the analysis of traditional tissue biopsy samples. To date, the majority of research in the area of liquid biopsies has focused on blood-based biomarkers, predominantly using plasma-derived ctDNA.[126] However, ctDNA can also be obtained from various nonblood sources, including urine, cerebrospinal fluid, and pleural or peritoneal fluid. A study that longitudinally assessed peritoneal cytology and plasma and peritoneal ctDNA in 11 patients with *KRAS*-mutated colorectal and appendiceal cancer who were at risk or with established peritoneal involvement before and after HIPEC found that 2 of 7 patients with proven carcinomatosis had positive peritoneal cytology. Patients with positive plasma ctDNA had systemic relapse, and those with negative peritoneal ctDNA after CRS and HIPEC did not present peritoneal relapse. The authors concluded that treatment with CRS and HIPEC does not always neutralize ctDNA in peritoneal fluid, and its persistence after treatment may predict disease recurrence.[111]

Although peritoneal ctDNA in patients with appendiceal neoplasms may play a complementary role for the prediction of peritoneal dissemination, future prospective and comparative studies are needed before incorporating peritoneal ctDNA in the diagnostic and treatment algorithms of patients with appendiceal neoplasms.

12. Patients with LAMNs with negative margins and no evidence of perforation or peritoneal involvement are safely treated with appendectomy alone. Strength of recommendation: strong recommendation based on moderate-quality evidence.

In contemporary observational studies, oncologic outcomes after appendectomy, including the entire mesoappendix for LAMNs without perforation or peritoneal involvement, have reported low recurrence rates, consistent with the indolent behavior of these neoplasms.[127–132] Appropriate initial surgical management is critical because iatrogenic rupture of the appendix can convert the situation from localized to disseminated. If an unruptured LAMN cannot be safely resected laparoscopically, conversion to an open operation is recommended.[127,128] In a review of 217 patients with localized LAMNs, recurrence was 15% in patients with perforation versus 0% in those without ($p < 0.001$).[128] Limited published data suggest that a microscopically positive resection margin after appendectomy for nonperforated LAMN does not predict disease recurrence and therefore does not warrant further treatment.[129,130] After surgical resection of localized LAMN without perforation or spillage, posttreatment surveillance may not be necessary.[115,128] A study reviewing 114 patients across 10 years from an 11-hospital network found that surveillance (with office visit, CT, MRI, colonoscopy, or tumor markers) was performed in 34% of patients, but none of these patients experienced tumor recurrence at a mean follow-up of 4.7 years.[114]

HAMNs without perforation or peritoneal involvement and a negative microscopic margin, when found incidentally in an appendectomy specimen, can generally be treated with appendectomy alone. However, care should be taken to exclude the presence of associated invasive adenocarcinoma, including a comprehensive histologic evaluation of the entire surgical specimen by an expert pathologist. Given the rarity and paucity of data on HAMNs, there should be a low threshold to review and discuss these cases in a multidisciplinary setting.

13. Patients with nonmetastatic adenocarcinoma of the appendix should undergo right hemicolectomy. However, in the setting of peritoneal spread, right hemicolectomy typically does not confer a survival benefit. Strength of recommendation: strong recommendation based on low-quality evidence.

In patients with appendiceal adenocarcinoma, the rate of metastatic disease to regional lymph nodes ranges from 20% to 67%, with positive nodes more likely in the nonmucinous subtype.[131–137] Because of this risk, the majority of patients with adenocarcinoma confined to the appendix should be treated with oncologic right hemicolectomy. Formal resection of the nodal basin allows for more complete staging, may have a therapeutic benefit, and can further guide the need for adjuvant systemic chemotherapy.[137–140] The recommendation for oncologic right colectomy also includes patients with appendiceal GCAs or tumors characterized by a mixture of histologic features of both neuroendocrine and epithelial adenocarcinoma.[141–143]

In the setting of peritoneal metastases, routine right hemicolectomy to remove clinically normal lymph nodes is not recommended. Several single-institution and retrospective observational studies have failed to demonstrate a survival benefit to right hemicolectomy versus appendectomy alone in patients undergoing CRS and HIPEC.[144–147] A Surveillance, Epidemiology, and End Results database study found that right colectomy was not associated with survival after adjusting for age, sex, T stage, metastatic disease, and histologic grade. Interestingly, median survival for patients having appendectomy compared with right hemicolectomy was similar, even in node-positive patients.[147] Despite these reservations, it should be noted that a right hemicolectomy is sometimes necessary to achieve a complete cytoreduction of peritoneal disease originating from the appendix.

14. CRS is indicated in select patients with appendiceal neoplasms and evidence of peritoneal involvement. Strength of recommendation: strong recommendation based on moderate-quality evidence.

Surgical resection remains the first-line treatment for patients with appendiceal neoplasms with peritoneal metastases. The goal of CRS is the eradication of all macroscopic diseases to be followed by intraperitoneal

Copyright © The American Society of Colon & Rectal Surgeons, Inc. Unauthorized reproduction of this article is prohibited.

chemotherapy, such as HIPEC (see subsequent recommendation). Typically, CRS entails peritonectomy of all involved surfaces, which may include the diaphragms, pelvis, bowel surface, complete omentectomy, and additional resections, depending on tumor involvement.[148–150] Even when the omentum appears macroscopically normal, omentectomy is typically recommended given the high risk of microscopic disease and low morbidity. Individualized decisions regarding CRS with or without HIPEC should be undertaken by a multidisciplinary team, preferably at experienced centers.[151–155] Proper patient selection is crucial in treating patients with peritoneal involvement from appendiceal neoplasms.[156] Findings on cross-sectional imaging may help determine resectability and guide the selection of suitable candidates for cytoreduction.[157,158] Diagnostic laparoscopy may also be used to estimate the likelihood of complete cytoreduction or to obtain tissue if other techniques such as CT-guided biopsy are not feasible to initially obtain a diagnosis. During CRS, the burden of peritoneal disease is quantified using the PCI or the Peritoneal Surface Disease Severity Score.[158–160] The PCI is calculated by dividing the abdomen into 13 regions, with each region receiving a score of 0 to 3 based on the size of the implants. Therefore, scores can range from 0 to 39. In contemporary, large cohorts evaluating clinical and pathologic factors, completeness of cytoreduction, whether performed open or laparoscopically, is consistently an independent predictor of outcome.[150–152,161–164] Even after grossly complete cytoreduction, peritoneal recurrences are common, ranging from 7% to 37%. Repeat cytoreduction can be considered on a case-by-case basis and depends on tumor histology, disease-free interval, burden of disease recurrence, and patient performance status.[165–169]

Women with a peritoneal spread often experience ovarian involvement, even with macroscopically normal ovaries. Metastatic ovarian tumors may grow rapidly and are typically resistant to systemic chemotherapy.[154,155] A retrospective study of 258 female patients with 1 or more remaining ovaries who underwent CRS and HIPEC for colorectal and appendiceal tumors found that 141 patients (55%) had ovarian tumor involvement. Of 40 patients with 1 macroscopic ovarian metastasis, microscopic involvement of the contralateral ovary was found in 18 patients (45%). Of 141 patients in whom both ovaries were macroscopically normal, 24 (17%) had microscopic ovarian involvement.[170] Given the risk of occult ovarian metastases in this patient population, bilateral salpingo-oophorectomy should be strongly considered (especially for postmenopausal women), and patients should be appropriately counseled preoperatively.[171,172]

The management of patients with limited peritoneal involvement of cellular or acellular mucin in the setting of LAMN remains controversial, particularly when it is isolated to the right lower quadrant.[173] Importantly, cellular versus acellular mucin can only be established after surgery (appendectomy or biopsy of a mucinous peritoneal implant), and the inability to rely on an intraoperative frozen section plays a pivotal role in this decision-making. Appendectomy with cytoreduction of the periappendiceal peritoneum in these cases has been associated with very low peritoneal recurrence rates between 0% and 5% and with similar outcomes comparing cytoreduction versus HIPEC.[8,115,173] Conversely, LAMNs associated with cellular mucin deposits are associated with a higher risk of subsequent peritoneal involvement (33%–78%); these patients should be surveyed closely and considered for cytoreduction and HIPEC.[116,174,175]

15. In patients with appendiceal epithelial neoplasms, intraperitoneal chemotherapy after CRS compared to CRS alone may reduce peritoneal disease recurrence, although its impact on overall survival is not established and has been associated with increased costs and toxicity. Strength of recommendation: strong recommendation based on moderate-quality evidence.

After complete resection of all gross peritoneal disease, patients with appendiceal neoplasms may be treated with intraperitoneal chemotherapy. Most commonly, this is performed concurrently with CRS through the delivery of HIPEC. A large randomized controlled trial for peritoneal carcinomatosis of colorectal origin demonstrated a doubling of survival for CRS and HIPEC compared with systemic chemotherapy alone (median overall survival 22.3 vs 12.6 months, $p = 0.032$).[176] Although only 18 of these 105 patients with peritoneal carcinomatosis were of appendiceal origin, additional long-term follow-up demonstrated a median disease-specific survival of 12.6 months in the control arm and 22.2 months in the HIPEC arm ($p = 0.028$) and a 5-year survival of 45% for those patients for whom a complete cytoreduction could be achieved.[177] Multiple large retrospective and prospective phase II studies, including patients with both low-grade and high-grade peritoneal disease, have demonstrated improved long-term patient survival, decreased tumor recurrence, longer time to disease progression, and less frequent repeat operative interventions in patients who undergo CRS plus HIPEC compared with CRS alone or palliative systemic chemotherapy.[16–18,178–186] Although retrospective, noncomparative data on HIPEC with low-grade peritoneal disease has shown improved short-term oncologic-specific outcomes compared to patients with high-grade peritoneal disease, prospective data do not exist. A 2012 observational study including 2,298 patients reported superior progression-free survival associated with HIPEC after CRS (HR 0.65; $p = 0.03$) for metastatic appendiceal mucinous neoplasm, but there was no overall survival difference in their multivariate analysis.[16] The median overall survival was 16.3 years, and the median progression-free survival was 8.2 years.[16]

Copyright © The American Society of Colon & Rectal Surgeons, Inc. Unauthorized reproduction of this article is prohibited.

The multicenter French open-label (PRODIGE 7) trial randomly assigned 265 patients with metastatic colorectal (not appendiceal) cancer (with PCI ≤25) undergoing CRS to either HIPEC (oxaliplatin) or no HIPEC.[187] The majority of patients had received systemic chemotherapy and had previous resection of the primary tumor. At a median follow-up of 64 months, overall survival and recurrence-free survival were similar (42 vs 41 months, HR 1.00, p = 0.99; and HR 0.91, p = 0.43, respectively), and grade 3 or worse adverse events at 30 days and 60 days were significantly associated with HIPEC (42% vs 32%, p = 0.083; and 26% vs 15%, p = 0.035, respectively). No such multicenter randomized clinical trial for appendiceal adenocarcinoma currently exists.

Mitomycin and oxaliplatin are the most common drugs used during HIPEC and have shown similar disease-free and overall survival rates, as well as toxicity, with a higher incidence of major complications and cost with oxaliplatin.[188–190] Both open and closed techniques for delivery of HIPEC have proven to be safe with no clear advantages regarding operative morbidity, postoperative complications, or oncologic-specific outcomes.[191] In addition, there is no clear consensus regarding the ideal duration or temperature of HIPEC.

Aside from HIPEC, other methods for delivering intraperitoneal chemotherapy include early postoperative intraperitoneal chemotherapy (EPIC) or delayed postoperative approaches.[19,192–199] Generally, similar results are obtained among the various approaches, and few head-to-head comparisons exist. A retrospective study of 93 patients in Norway compared EPIC and HIPEC after complete cytoreduction and showed no difference in 10-year overall survival and disease-free survival.[19] All 93 patients with colorectal or high-grade appendiceal carcinomatosis were treated with CRS and HIPEC + EPIC or HIPEC alone. Three-year overall and recurrence-free survival rates were 50% and 21% for HIPEC + EPIC and 46% and 6% for HIPEC alone (p = 0.72 and p = 0.89, respectively). HIPEC + EPIC patients experienced more grade III/IV complications (43% vs 20%, p = 0.01).[19]

16. Systemic chemotherapy may improve survival in patients with metastatic and lymph node–positive disease, HAMNs, and adenocarcinoma with peritoneal metastases. Routine use of systemic chemotherapy for LAMNs or well-differentiated mucinous adenocarcinoma with peritoneal spread is not recommended. Strength of recommendation: strong recommendation based on low-quality evidence.

The role of systemic chemotherapy and the optimal chemotherapeutic drug regimen for the treatment of metastatic mucinous and nonmucinous appendiceal adenocarcinoma, signet-ring cell carcinoma, or high-grade GCA continues to be investigated because of the rarity and heterogeneity of these neoplasms. Although there is no level I evidence, a multimodal approach using systemic chemotherapy, such as that commonly used for metastatic colorectal cancer, is typically recommended for patients with high-grade and metastatic disease.[200,201] One study of 109 patients showed no discernible benefit in progression-free survival (13.6 vs 13.6 months, p = 0.59) or overall survival (34.6 vs 29.3 months, p = 0.98) with the use of perioperative systemic chemotherapy compared with CRS and HIPEC alone.[202] The use of perioperative systemic chemotherapy showed improved progression-free survival in patients with incomplete cytoreductions (8.6 vs 4.8 months, p = 0.05) or had signet-ring cells (10.9 vs 4.8 months, p = 0.06). Another study of 103 patients reported that the median overall survival for non–low-grade and well-differentiated tumor patients who received adjuvant chemotherapy after complete cytoreduction was 9.03 years compared with 2.88 years for patients who did not receive adjuvant chemotherapy (p = 0.02).[135] The authors also noted that systemic chemotherapy for low-grade cancers was not beneficial in terms of overall survival.

Although the timing of perioperative systemic chemotherapy has shown conflicting results, there are several potential advantages of preoperative chemotherapy, including the ability to assess disease response and patient tolerance, potentially downstage tumors, and allow for as-yet-undeclared distant metastatic disease to appear on imaging and possibly preclude CRS of questionable benefit.[46,203,204] A prospective study comparing preoperative systemic chemotherapy (n = 34) or not (n = 24) in patients with peritoneal carcinomatosis of appendiceal origin showed a complete or near complete histological response in 29% of patients who received preoperative systemic chemotherapy. Patients receiving preoperative systemic chemotherapy had a lower PCI (p = 0.0003), required fewer visceral resections (2.7 vs 4.4), and achieved complete cytoreduction more frequently compared to patients with no preoperative chemotherapy. The incidence of perioperative complications (p = 0.16) and overall survival were not significantly different between the 2 groups (37.2 vs 50.5 months; p = 0.56). However, among the patients who received neoadjuvant chemotherapy, survival was significantly better for patients who experienced a histological complete or near complete response (p = 0.033).[205]

LAMN with or without peritoneal spread is considered an indolent process, which generally shows minimal to no response to systemic chemotherapy. Thus, CRS with or without HIPEC is the mainstay of treatment when possible.[202–204,206] For patients with unresectable LAMN or recurrent disease that is not amenable to CRS and HIPEC, systemic chemotherapy may be used, though minimal benefit has been found in this subgroup of patients.[201–204,207]

17. Minimally invasive aerosolized approaches to peritoneal carcinomatosis require specialized equipment and expertise and have shown acceptable short-term

Copyright © The American Society of Colon & Rectal Surgeons, Inc. Unauthorized reproduction of this article is prohibited.

oncologic outcomes, but there is a paucity of long-term data. Strength of recommendation: conditional recommendation based on low-quality evidence.

Pressurized intraperitoneal aerosol chemotherapy (PIPAC) has been developed as a potential alternative surgical technique in the palliative setting for peritoneal metastases that are not amendable to CRS-HIPEC. PIPAC uses a minimally invasive approach with repeated administration of aerosolized chemotherapy with potential for enhanced pharmacokinetics.[208–211] The technique has shown a good safety profile and encouraging oncological results for primary and metastatic peritoneal malignancies.[212–215] However, PIPAC has been used in a heterogeneous group of peritoneal malignancies, and there are currently limited data on its utilization in patients with appendiceal neoplasms and peritoneal involvement.

A recent multi-institutional study of 77 consecutive patients with appendiceal peritoneal metastases who underwent 208 PIPAC procedures (45% had 3 or more procedures and the majority with oxaliplatin) showed a complete response in 11% and partial/stable response in 31%. Peritoneal cytology and PCI did not influence treatment response. For patients who underwent at least 3 PIPAC treatments, the overall survival was 22 months.[209]

Clinical trials are currently underway examining the role of PIPAC in patients with unresectable appendiceal, colorectal, ovarian, uterine, and gastric cancers (NCT04329494).[210–222]

REFERENCES

1. Marmor S, Portschy PR, Tuttle TM, Virnig BA. The rise in appendiceal cancer incidence: 2000-2009. *J Gastrointest Surg*. 2015;19:743–750.
2. McCusker ME, Coté TR, Clegg LX, Sobin LH. Primary malignant neoplasms of the appendix: a population-based study from the surveillance, epidemiology and end-results program, 1973-1998. *Cancer*. 2002;94:3307–3312.
3. Hanna M, Hwang G, Moghadamyeghaneh Z, et al. Incidental appendiceal cancer at appendectomy: an analysis of incidence, trends and risk factors. *Dis Colon Rectum*. 2015;58:E339.
4. van den Heuvel MG, Lemmens VE, Verhoeven RH, de Hingh IH. The incidence of mucinous appendiceal malignancies: a population-based study. *Int J Colorectal Dis*. 2013;28:1307–1310.
5. Singh H, Koomson AS, Decker KM, Park J, Demers AA. Continued increasing incidence of malignant appendiceal tumors in Canada and the United States: a population-based study. *Cancer*. 2020;126:2206–2216.
6. Hanna N, Hanna AN, Hanna DN. AJCC Cancer Staging System Version 9: appendiceal adenocarcinoma. *Ann Surg Oncol*. 2024;31:2177–2180.
7. Smeenk RM, van Velthuysen ML, Verwaal VJ, Zoetmulder FA. Appendiceal neoplasms and pseudomyxoma peritonei: a population based study. *Eur J Surg Oncol*. 2008;34:196–201.
8. Tiselius C, Kindler C, Shetye J, Letocha H, Smedh K. Computed tomography follow-up assessment of patients with low-grade appendiceal mucinous neoplasms: evaluation of risk for pseudomyxoma peritonei. *Ann Surg Oncol*. 2017;24:1778–1782.
9. Nagtegaal ID, Odze RD, Klimstra D, et al; WHO Classification of Tumours Editorial Board. The 2019 WHO classification of tumours of the digestive system. *Histopathology*. 2020;76:182–188.
10. Fournier KF, Royal R, Lambert LA, Taggart M, Rafeeq S, Mansfield PF. Mucinous appendiceal tumors of uncertain malignant potential (UMP): prognostic factors and implications for treatment and follow-up. *J Clin Oncol*. 2011;29:372–372.
11. Carr NJ, Bibeau F, Bradley RF, et al. The histopathological classification, diagnosis and differential diagnosis of mucinous appendiceal neoplasms, appendiceal adenocarcinomas and pseudomyxoma peritonei. *Histopathology*. 2017;71:847–858.
12. Brathwaite S, Rock J, Yearsley MM, et al. Mixed adenoneuroendocrine carcinoma: an aggressive clinical entity. *Ann Surg Oncol*. 2016;23:2281–2286.
13. Turaga KK, Pappas SG, Gamblin T. Importance of histologic subtype in the staging of appendiceal tumors. *Ann Surg Oncol*. 2012;19:1379–1385.
14. Tang LH, Shia J, Soslow RA, et al. Pathologic classification and clinical behavior of the spectrum of goblet cell carcinoid tumors of the appendix. *Am J Surg Pathol*. 2008;32:1429–1443.
15. Cerame MA. A 25-year review of adenocarcinoma of the appendix. A frequently perforating carcinoma. *Dis Colon Rectum*. 1988;31:145–150.
16. Chua TC, Moran BJ, Sugarbaker PH, et al. Early- and long-term outcome data of patients with pseudomyxoma peritonei from appendiceal origin treated by a strategy of cytoreductive surgery and hyperthermic intraperitoneal chemotherapy. *J Clin Oncol*. 2012;30:2449–2456.
17. Carr NJ, Cecil TD, Mohamed F, et al; Peritoneal Surface Oncology Group International. A consensus for classification and pathologic reporting of pseudomyxoma peritonei and associated appendiceal neoplasia: the results of the Peritoneal Surface Oncology Group International (PSOGI) modified Delphi process. *Am J Surg Pathol*. 2016;40:14–26.
18. Smeenk RM, Verwaal VJ, Antonini N, Zoetmulder FA. Survival analysis of pseudomyxoma peritonei patients treated by cytoreductive surgery and hyperthermic intraperitoneal chemotherapy. *Ann Surg*. 2007;245:104–109.
19. Sørensen O, Flatmark K, Reed W, et al. Evaluation of complete cytoreductive surgery and two intraperitoneal chemotherapy techniques in pseudomyxoma peritonei. *Eur J Surg Oncol*. 2012;38:969–976.
20. Davison JM, Choudry HA, Pingpank JF, et al. Clinicopathologic and molecular analysis of disseminated appendiceal mucinous neoplasms: identification of factors predicting survival and proposed criteria for a three-tiered assessment of tumor grade. *Mod Pathol*. 2014;27:1521–1539.
21. Shetty S, Natarajan B, Thomas P, Govindarajan V, Sharma P, Loggie B. Proposed classification of pseudomyxoma peritonei: influence of signet ring cells on survival. *Am Surg*. 2013;79:1171–1176.
22. Glasgow SC, Gaertner W, Stewart D, et al. The American Society of Colon and Rectal Surgeons, clinical practice guidelines for the management of appendiceal neoplasms. *Dis Colon Rectum*. 2019;62:1425–1438.

Copyright © The American Society of Colon & Rectal Surgeons, Inc. Unauthorized reproduction of this article is prohibited.

23. Brouwers MC, Kerkvliet K, Spithoff K; AGREE Next Steps Consortium. The AGREE Reporting Checklist: a tool to improve reporting of clinical practice guidelines. *BMJ*. 2016;352:i1152. Erratum BMJ. 2016;354:i4852.
24. Lohsiriwat V, Vongjirad A, Lohsiriwat D. Incidence of synchronous appendiceal neoplasm in patients with colorectal cancer and its clinical significance. *World J Surg Oncol*. 2009;7:51.
25. Trivedi AN, Levine EA, Mishra G. Adenocarcinoma of the appendix is rarely detected by colonoscopy. *J Gastrointest Surg*. 2009;13:668–675.
26. Park KB, Park JS, Choi GS, et al. Single-incision laparoscopic surgery for appendiceal mucoceles: safety and feasibility in a series of 16 consecutive cases. *J Korean Soc Coloproctol*. 2011;27:287–292.
27. Bucher P, Gervaz P, Ris F, Oulhaci W, Inan I, Morel P. Laparoscopic versus open resection for appendix carcinoid. *Surg Endosc*. 2006;20:967–970.
28. Shindholimath VV, Thinakaran K, Rao TN, Veerappa YV. Laparoscopic management of appendicular mass. *J Minim Access Surg*. 2011;7:136–140.
29. Kim TK, Park JH, Kim JY, et al. Safety and feasibility of laparoscopic surgery for appendiceal mucocele: a multicenter study. *Surg Endosc*. 2018;32:4408–4414.
30. Cheng A, Li M, Kanis MJ, et al. Is it necessary to perform routine appendectomy for mucinous ovarian neoplasms? A retrospective study and meta-analysis. *Gynecol Oncol*. 2017;144:215–222.
31. Kleppe M, Bruls J, Van Gorp T, et al. Mucinous borderline tumours of the ovary and the appendix: a retrospective study and overview of the literature. *Gynecol Oncol*. 2014;133:155–158.
32. Feigenberg T, Covens A, Ghorab Z, et al. Is routine appendectomy at the time of primary surgery for mucinous ovarian neoplasms beneficial? *Int J Gynecol Cancer*. 2013;23:1205–1209.
33. Tekin A, Kurtoğlu HC, Can I, Öztan S. Routine interval appendectomy is unnecessary after conservative treatment of appendiceal mass. *Colorectal Dis*. 2008;10:465–468.
34. Kaminski A, Liu IL, Applebaum H, Lee SL, Haigh PI. Routine interval appendectomy is not justified after initial nonoperative treatment of acute appendicitis. *Arch Surg*. 2005;140:897–901.
35. Teixeira FJR Jr, Couto Netto SDD, Akaishi EH, Utiyama EM, Menegozzo CAM, Rocha MC. Acute appendicitis, inflammatory appendiceal mass and the risk of a hidden malignant tumor: a systematic review of the literature. *World J Emerg Surg*. 2017;12:12.
36. Carpenter SG, Chapital AB, Merritt MV, Johnson DJ. Increased risk of neoplasm in appendicitis treated with interval appendectomy: single-institution experience and literature review. *Am Surg*. 2012;78:339–343.
37. Connor SJ, Hanna GB, Frizelle FA. Appendiceal tumors: retrospective clinicopathologic analysis of appendiceal tumors from 7,970 appendectomies. *Dis Colon Rectum*. 1998;41:75–80.
38. Deakin DE, Ahmed I. Interval appendicectomy after resolution of adult inflammatory appendix mass—is it necessary? *Surgeon*. 2007;5:45–50.
39. Tannoury J, Abboud B. Treatment options of inflammatory appendiceal masses in adults. *World J Gastroenterol*. 2013;19:3942–3950.
40. Wright GP, Mater ME, Carroll JT, Choy JS, Chung MH. Is there truly an oncologic indication for interval appendectomy? *Am J Surg*. 2015;209:442–446.
41. Mällinen J, Rautio T, Grönroos J, et al. Risk of appendiceal neoplasm in periappendicular abscess in patients treated with interval appendectomy vs follow-up with magnetic resonance imaging: 1-year outcomes of the peri-appendicitis acuta randomized clinical trial. *JAMA Surg*. 2019;154:200–207.
42. Furman MJ, Cahan M, Cohen P, Lambert LA. Increased risk of mucinous neoplasm of the appendix in adults undergoing interval appendectomy. *JAMA Surg*. 2013;148:703–706.
43. Hayes D, Reiter S, Hagen E, et al. Is interval appendectomy really needed? A closer look at neoplasm rates in adult patients undergoing interval appendectomy after complicated appendicitis. *Surg Endosc*. 2021;35:3855–3860.
44. Sugimoto T, Nagasue Y, Tanaka E, Yokomizo H. Comparison of the risk of appendiceal tumors in uncomplicated and complicated appendicitis. *Surg Endosc*. 2022;36:8107–8111.
45. Peltrini R, Cantoni V, Green R, et al. Risk of appendiceal neoplasm after interval appendectomy for complicated appendicitis: a systematic review and meta-analysis. *Surgeon*. 2021;19:e549–e558.
46. Chicago Consensus Working Group. The Chicago Consensus on peritoneal surface malignancies: management of appendiceal neoplasms. *Cancer*. 2020;126:2525–2533.
47. Alexandraki KI, Kaltsas GA, Grozinsky-Glasberg S, Chatzellis E, Grossman AB. Appendiceal neuroendocrine neoplasms: diagnosis and management. *Endocr Relat Cancer*. 2016;23:R27–R41.
48. Bednarczuk T, Zemczak A, Bolanowski M, et al. Neuroendocrine neoplasms of the small intestine and the appendix—update of the diagnostic and therapeutic guidelines (recommended by the Polish Network of Neuroendocrine Tumours) [Nowotwory neuroendokrynne jelita cienkiego i wyrostka robaczkowego—uaktualnione zasady diagnostyki i leczenia (rekomendowane przez Polską Sieć Guzów Neuroendokrynnych)]. *Endokrynol Pol*. 2022;73:549–583.
49. Huang ES, Chumfong IT, Alkoraishi AS, Munroe CA. Combined endoscopic mucosal resection and extended laparoscopic appendectomy for the treatment of periappendiceal, cecal, and appendiceal adenomas. *J Surg Res*. 2020;252:89–95.
50. Ichkhanian Y, Barawi M, Seoud T, et al. Endoscopic full-thickness resection of polyps involving the appendiceal orifice: a multicenter international experience. *Endoscopy*. 2022;54:16–24.
51. Janson ET, Holmberg L, Stridsberg M, et al. Carcinoid tumors: analysis of prognostic factors and survival in 301 patients from a referral center. *Ann Oncol*. 1997;8:685–690.
52. Modlin IM, Lye KD, Kidd M. A 5-decade analysis of 13,715 carcinoid tumors. *Cancer*. 2003;97:934–959.
53. Lal P, Saleh MA, Khoudari G, et al. Epidemiology of large bowel carcinoid tumors in the USA: a population-based national study. *Dig Dis Sci*. 2020;65:269–275.
54. Wu YC, Wen L, Dou WD, Zhang JL, Wu T, Wang X. Clinicopathological analysis and surgical strategy of primary appendiceal neoplasms. *Zhonghua Wei Chang Wai Ke Za Zhi*. 2021;24:1065–1072.
55. Heller DR, Jean RA, Luo J, et al. Practice patterns and guideline non-adherence in surgical management of appendiceal carcinoid tumors. *J Am Coll Surg*. 2019;228:839–851. Erratum J Am Coll Surg. 2020;231:610–611.
56. Uhlén N, Grundberg O, Jacobsson H, et al. 18F-FDG PET/CT diagnosis of bronchopulmonary carcinoids versus pulmonary hamartomas. *Clin Nucl Med*. 2016;41:263–267.

Copyright © The American Society of Colon & Rectal Surgeons, Inc. Unauthorized reproduction of this article is prohibited.

57. Deppen SA, Liu E, Blume JD, et al. Safety and efficacy of 68Ga-DOTATATE PET/CT for diagnosis, staging, and treatment management of neuroendocrine tumors. *J Nucl Med*. 2016;57:708–714.
58. Etchebehere EC, de Oliveira Santos A, Gumz B, et al. 68Ga-DOTATATE PET/CT, 99mTc-HYNIC-octreotide SPECT/CT, and whole-body MR imaging in detection of neuroendocrine tumors: a prospective trial. *J Nucl Med*. 2014;55:1598–1604.
59. Crown A, Rocha FG, Raghu P, et al. Impact of initial imaging with gallium-68 DOTATATE PET/CT on diagnosis and management of patients with neuroendocrine tumors. *J Surg Oncol*. 2020;121:480–485.
60. Naswa N, Sharma P, Gupta SK, et al. Dual tracer functional imaging of gastroenteropancreatic neuroendocrine tumors using 68Ga-DOTA-NOC PET-CT and 18F-FDG PET-CT: competitive or complimentary? *Clin Nucl Med*. 2014;39:e27–e34.
61. Has Simsek D, Kuyumcu S, Turkmen C, et al. Can complementary 68Ga-DOTATATE and 18F-FDG PET/CT establish the missing link between histopathology and therapeutic approach in gastroenteropancreatic neuroendocrine tumors? *J Nucl Med*. 2014;55:1811–1817.
62. Evangelista L, Ravelli I, Bignotto A, Cecchin D, Zucchetta P. Ga-68 DOTA-peptides and F-18 FDG PET/CT in patients with neuroendocrine tumor: a review. *Clin Imaging*. 2020;67:113–116.
63. Ilhan H, Fendler WP, Cyran CC, et al. Impact of (68) Ga-DOTATATE PET/CT on the surgical management of primary neuroendocrine tumors of the pancreas or ileum. *Ann Surg Oncol*. 2015;22:164–171.
64. Panagiotidis E, Alshammari A, Michopoulou S, et al. Comparison of the impact of 68Ga-DOTATATE and 18F-FDG PET/CT on clinical management in patients with neuroendocrine tumors. *J Nucl Med*. 2017;58:91–96.
65. Hofland J, Feelders RA, Brabander T, Franssen GJH, de Herder WW. Recent developments in the diagnosis and therapy of well-differentiated neuroendocrine tumours. *Neth J Med*. 2018;76:100–108.
66. Modlin IM, Moss SF, Oberg K, et al. Gastrointestinal neuroendocrine (carcinoid) tumours: current diagnosis and management. *Med J Aust*. 2010;193:46–52.
67. Di Giacinto P, Rota F, Rizza L, et al. Chromogranin A: from laboratory to clinical aspects of patients with neuroendocrine tumors. *Int J Endocrinol*. 2018;2018:8126087.
68. Öberg K, Califano A, Strosberg JR, et al. A meta-analysis of the accuracy of a neuroendocrine tumor mRNA genomic biomarker (NETest) in blood. *Ann Oncol*. 2020;31:202–212.
69. Puliani G, Di Vito V, Feola T, et al. NETest: a systematic review focusing on the prognostic and predictive role. *Neuroendocrinology*. 2022;112:523–536.
70. Malczewska A, Witkowska M, Wójcik-Giertuga M, et al. Prospective evaluation of the NETest as a liquid biopsy for gastroenteropancreatic and bronchopulmonary neuroendocrine tumors: an ENETS center of excellence experience. *Neuroendocrinology*. 2021;111:304–319.
71. Mullen JT, Savarese DM. Carcinoid tumors of the appendix: a population-based study. *J Surg Oncol*. 2011;104:41–44.
72. Hsu C, Rashid A, Xing Y, et al. Varying malignant potential of appendiceal neuroendocrine tumors: importance of histologic subtype. *J Surg Oncol*. 2013;107:136–143.
73. Pape UF, Niederle B, Costa F, et al; Vienna Consensus Conference participants. ENETS consensus guidelines for neuroendocrine neoplasms of the appendix (excluding goblet cell carcinomas). *Neuroendocrinology*. 2016;103:144–152.
74. In't Hof KH, van der Wal HC, Kazemier G, Lange JF. Carcinoid tumour of the appendix: an analysis of 1,485 consecutive emergency appendectomies. *J Gastrointest Surg*. 2008;12:1436–1438.
75. Ciarrocchi A, Pietroletti R, Carlei F, Amicucci G. Clinical significance of metastatic lymph nodes in the gut of patients with pure and mixed primary appendiceal carcinoids. *Dis Colon Rectum*. 2016;59:508–512.
76. Brighi N, La Rosa S, Rossi G, et al. Morphological factors related to nodal metastases in neuroendocrine tumors of the appendix: a multicentric retrospective study. *Ann Surg*. 2020;271:527–533.
77. Ricci C, Ingaldi C, Alberici L, et al. Histopathological diagnosis of appendiceal neuroendocrine neoplasms: when to perform a right hemicolectomy? A systematic review and meta-analysis. *Endocrine*. 2019;66:460–466.
78. Rault-Petit B, Do Cao C, Guyétant S, et al. Current management and predictive factors of lymph node metastasis of appendix neuroendocrine tumors: a national study from the French Group of Endocrine Tumors (GTE). *Ann Surg*. 2019;270:165–171.
79. Kleiman DA, Finnerty B, Beninato T, et al. Features associated with metastases among well-differentiated neuroendocrine (carcinoid) tumors of the appendix: the significance of small vessel invasion in addition to size. *Dis Colon Rectum*. 2015;58:1137–1143.
80. Blakely AM, Raoof M, Ituarte PHG, Fong Y, Singh G, Lee B. Lymphovascular invasion is associated with lymph node involvement in small appendiceal neuroendocrine tumors. *Ann Surg Oncol*. 2019;26:4008–4015.
81. Volante M, Daniele L, Asioli S, et al. Tumor staging but not grading is associated with adverse clinical outcome in neuroendocrine tumors of the appendix: a retrospective clinical pathologic analysis of 138 cases. *Am J Surg Pathol*. 2013;37:606–612.
82. Moertel CG, Weiland LH, Nagorney DM, Dockerty MB. Carcinoid tumor of the appendix: treatment and prognosis. *N Engl J Med*. 1987;317:1699–1701.
83. Shapiro R, Eldar S, Sadot E, Papa MZ, Zippel DB. Appendiceal carcinoid at a large tertiary center: pathologic findings and long-term follow-up evaluation. *Am J Surg*. 2011;201:805–808.
84. Fornaro R, Frascio M, Sticchi C, et al. Appendectomy or right hemicolectomy in the treatment of appendiceal carcinoid tumors? *Tumori*. 2007;93:587–590.
85. Boudreaux JP, Klimstra DS, Hassan MM, et al; North American Neuroendocrine Tumor Society (NANETS). The NANETS consensus guideline for the diagnosis and management of neuroendocrine tumors: well-differentiated neuroendocrine tumors of the jejunum, ileum, appendix, and cecum. *Pancreas*. 2010;39:753–766.
86. Vinagre J, Pinheiro J, Martinho O, et al. A 30-Year long-term experience in appendix neuroendocrine neoplasms—granting a positive outcome. *Cancers (Basel)*. 2020;12:1357.
87. Yildirim E, Kegin M, Özdemir M, Bektaş S, Pelen Z, Er M. Neoplasms of the appendix: single institution and ten-year experiences results. *Ulus Travma Acil Cerrahi Derg*. 2022;28:352–360.
88. Murray SE, Lloyd RV, Sippel RS, Chen H, Oltmann SC. Postoperative surveillance of small appendiceal carcinoid tumors. *Am J Surg*. 2014;207:342–345.

Copyright © The American Society of Colon & Rectal Surgeons, Inc. Unauthorized reproduction of this article is prohibited.

89. Wu YC, Wen L, Dou WD, Zhang JL, Wu T, Wang X. Clinicopathological analysis and surgical strategy of primary appendiceal neoplasms. *Zhonghua Wei Chang Wai Ke Za Zhi*. 2021;24:1065–1072.
90. Volante M, Grillo F, Massa F, et al. Neuroendocrine neoplasms of the appendix, colon and rectum. *Pathologica*. 2021;113:19–27.
91. Holmager P, Willemoe GL, Nielsen K, et al. Neuroendocrine neoplasms of the appendix: characterization of 335 patients referred to the Copenhagen NET Center of Excellence. *Eur J Surg Oncol*. 2021;47:1357–1363.
92. Ahmed M. Gastrointestinal neuroendocrine tumors in 2020. *World J Gastrointest Oncol*. 2020;12:791–807.
93. Rossi RE, Ciafardini C, Sciola V, Conte D, Massironi S. Chromogranin A in the follow-up of gastroenteropancreatic neuroendocrine neoplasms: is it really game over? A systematic review and meta-analysis. *Pancreas*. 2018;47:1249–1255.
94. Plöckinger U, Couvelard A, Falconi M, et al; Frascati Consensus Conference participants. Consensus guidelines for the management of patients with digestive neuroendocrine tumours: well-differentiated tumour/carcinoma of the appendix and goblet cell carcinoma. *Neuroendocrinology*. 2008;87:20–30.
95. Maroun J, Kocha W, Kvols L, et al. Guidelines for the diagnosis and management of carcinoid tumours. Part 1: the gastrointestinal tract. A statement from a Canadian National Carcinoid Expert Group. *Curr Oncol*. 2006;13:67–76.
96. Frilling A, Malago M, Martin H, Broelsch CE. Use of somatostatin receptor scintigraphy to image extrahepatic metastases of neuroendocrine tumors. *Surgery*. 1998;124:1000–1004.
97. Muñoz de Nova JL, Hernando J, Sampedro Núñez M, et al. Management of incidentally discovered appendiceal neuroendocrine tumors after an appendicectomy. *World J Gastroenterol*. 2022;28:1304–1314.
98. Munoz-Zuluaga CA, Sardi A, MacDonald R, et al. The role of preoperative tumor markers in patients with peritoneal carcinomatosis from appendiceal cancer undergoing cytoreductive surgery and hyperthermic intraperitoneal chemotherapy. *Ann Surg Oncol*. 2018;25:S155–S1S6.
99. van Ruth S, Hart AA, Bonfrer JM, Verwaal VJ, Zoetmulder FA. Prognostic value of baseline and serial carcinoembryonic antigen and carbohydrate antigen 19.9 measurements in patients with pseudomyxoma peritonei treated with cytoreduction and hyperthermic intraperitoneal chemotherapy. *Ann Surg Oncol*. 2002;9:961–967.
100. Di Fabio F, Aston W, Mohamed F, Chandrakumaran K, Cecil T, Moran B. Elevated tumour markers are normalized in most patients with pseudomyxoma peritonei 7 days after complete tumour removal. *Colorectal Dis*. 2015;17:698–703.
101. Taflampas P, Dayal S, Chandrakumaran K, Mohamed F, Cecil TD, Moran BJ. Pre-operative tumour marker status predicts recurrence and survival after complete cytoreduction and hyperthermic intraperitoneal chemotherapy for appendiceal pseudomyxoma peritonei: analysis of 519 patients. *Eur J Surg Oncol*. 2014;40:515–520.
102. Fackche N, Schmocker RK, Kubi B, et al. The utility of preoperative tumor markers in peritoneal carcinomatosis from primary appendiceal adenocarcinoma: an analysis from the US HIPEC collaborative. *J Gastrointest Surg*. 2021;25:2908–2919.
103. Low RN, Barone RM, Lee MJ. Surveillance MR imaging is superior to serum tumor markers for detecting early tumor recurrence in patients with appendiceal cancer treated with surgical cytoreduction and HIPEC. *Ann Surg Oncol*. 2013;20:1074–1081.
104. Szych C, Staebler A, Connolly DC, Wu R, Cho KR, Ronnett BM. Molecular genetic evidence supporting the clonality and appendiceal origin of Pseudomyxoma peritonei in women. *Am J Pathol*. 1999;154:1849–1855.
105. Raghav KP, Shetty AV, Kazmi SM, et al. Impact of molecular alterations and targeted therapy in appendiceal adenocarcinomas. *Oncologist*. 2013;18:1270–1277.
106. Goldstein DA, Elvin JA, Wang K, et al. Comprehensive genomic profiling of cancer of the appendix to reveal new routes to targeted therapies. *J Clin Oncol*. 2015;33:608–608.
107. Levine EA, Votanopoulos KI, Qasem SA, et al. Prognostic molecular subtypes of low-grade cancer of the appendix. *J Am Coll Surg*. 2016;222:493–503.
108. Shaib WL, Zakka K, Staley C III, et al. Blood-based next-generation sequencing analysis of appendiceal cancers. *Oncologist*. 2020;25:414–421.
109. López-Rojo I, Olmedillas-López S, Villarejo Campos P, et al. Liquid biopsy in peritoneal fluid and plasma as a prognostic factor in advanced colorectal and appendiceal tumors after complete cytoreduction and hyperthermic intraperitoneal chemotherapy. *Ther Adv Med Oncol*. 2020;12:1758835920981351.
110. Rohani P, Scotti SD, Shen P, et al. Use of FDG-PET imaging for patients with disseminated cancer of the appendix. *Am Surg*. 2010;76:1338–1344.
111. Low RN, Barone RM, Lucero J. Comparison of MRI and CT for predicting the peritoneal cancer index (PCI) preoperatively in patients being considered for cytoreductive surgical procedures. *Ann Surg Oncol*. 2015;22:1708–1715.
112. Dineen SP, Royal RE, Hughes MS, et al. A simplified preoperative assessment predicts complete cytoreduction and outcomes in patients with low-grade mucinous adenocarcinoma of the appendix. *Ann Surg Oncol*. 2015;22:3640–3646.
113. Low RN, Barone RM. Combined diffusion-weighted and gadolinium-enhanced MRI can accurately predict the peritoneal cancer index preoperatively in patients being considered for cytoreductive surgical procedures. *Ann Surg Oncol*. 2012;19:1394–1401.
114. Gupta AR, Brajcich BC, Yang AD, Bentrem DJ, Merkow RP. Necessity of posttreatment surveillance for low-grade appendiceal mucinous neoplasms. *J Surg Oncol*. 2021;124:1115–1120.
115. Guaglio M, Sinukumar S, Kusamura S, et al. Clinical surveillance after macroscopically complete surgery for low-grade appendiceal mucinous neoplasms (LAMN) with or without limited peritoneal spread: long-term results in a prospective series. *Ann Surg Oncol*. 2018;25:878–884.
116. Roxburgh CS, Fenig YM, Cercek A, et al. Outcomes of low-grade appendiceal mucinous neoplasms with remote acellular mucinous peritoneal deposits. *Ann Surg Oncol*. 2019;26:118–124.
117. Solomon D, Bekhor E, Leigh N, et al. Surveillance of low-grade appendiceal mucinous neoplasms with peritoneal metastases after cytoreductive surgery and hyperthermic intraperitoneal chemotherapy: are 5 years enough? A multisite experience. *Ann Surg Oncol*. 2020;27:147–153. Published correction appears in Ann Surg Oncol. 2019;26(Suppl 3):890.
118. Van Hooser A, Williams TR, Myers DT. Mucinous appendiceal neoplasms: pathologic classification, clinical

Copyright © The American Society of Colon & Rectal Surgeons, Inc. Unauthorized reproduction of this article is prohibited.

implications, imaging spectrum and mimics. *Abdom Radiol (NY)*. 2018;43:2913–2922.
119. Govaerts K, Chandrakumaran K, Carr NJ, et al. Single centre guidelines for radiological follow-up based on 775 patients treated by cytoreductive surgery and HIPEC for appendiceal pseudomyxoma peritonei. *Eur J Surg Oncol*. 2018;44:1371–1377.
120. Choudry HA, Pai RK. Management of mucinous appendiceal tumors. *Ann Surg Oncol*. 2018;25:2135–2144.
121. Endo S, Ikenaga M, Ohta K, et al. Prognostic factors for cytology-positive gastric cancer. *Surg Today*. 2019;49:56–64.
122. Jimenez RE, Warshaw AL, Fernandez-Del Castillo C. Laparoscopy and peritoneal cytology in the staging of pancreatic cancer. *J Hepatobiliary Pancreat Surg*. 2000;7:15–20.
123. Zuna RE, Behrens A. Peritoneal washing cytology in gynecologic cancers: long-term follow-up of 355 patients. *J Natl Cancer Inst*. 1996;88:980–987.
124. Trilling B, Cotte E, Vaudoyer D, et al. Intraperitoneal-free cancer cells represent a major prognostic factor in colorectal peritoneal carcinomatosis. *Dis Colon Rectum*. 2016;59:615–622.
125. Yonemura Y, Canbay E, Shintani H, et al. Treatment failure following complete cytoreductive surgery for peritoneal metastasis from colorectal cancer. *Gan To Kagaku Ryoho*. 2016;43:1435–1439.
126. Tivey A, Church M, Rothwell D, Dive C, Cook N. Circulating tumour DNA—looking beyond the blood. *Nat Rev Clin Oncol*. 2022;19:600–612.
127. Ballentine SJ, Carr J, Bekhor EY, Sarpel U, Polydorides AD. Updated staging and patient outcomes in low-grade appendiceal mucinous neoplasms. *Mod Pathol*. 2021;34:104–115.
128. Baumgartner JM, Srivastava A, Melnitchouk N, et al. A multi-institutional study of peritoneal recurrence following resection of low-grade appendiceal mucinous neoplasms. *Ann Surg Oncol*. 2021;28:4685–4694.
129. Gok M, Topal U, Akyüz M, Öz AB, Sozuer E, Deniz K. Long-term results of low grade appendiceal mucinous neoplasm (LAMN): a retrospective analysis of 24 patients. *Arch Iran Med*. 2021;24:615–621.
130. Sueda S, Young S, Sung M, Hotta M, O'Connor V, Leung AM. Predictors of progression of appendiceal mucinous neoplasm to pseudomyxoma peritonei. *Am Surg*. 2020;86:1379–1384.
131. Hegg KS, Mack LA, Bouchard-Fortier A, Temple WJ, Gui X. Macroscopic and microscopic characteristics of low grade appendiceal mucinous neoplasms (LAMN) on appendectomy specimens and correlations with pseudomyxoma peritonei development risk. *Ann Diagn Pathol*. 2020;48:151606.
132. Young S, Sueda SK, Hotta M, Sung ML, O'Connor VV, Leung AM. Surgical management of appendiceal mucinous neoplasm: is appendectomy sufficient? *J Surg Oncol*. 2020;122:1173–1178.
133. Webb C, Chang YH, Pockaj BA, Gray RJ, Stucky CC, Wasif N. Lymph node positivity and association with long-term survival for different histologies of appendiceal cancer. *J Surg Oncol*. 2021;124:88–96.
134. Jedrzkiewicz J, Tateishi Y, Kirsch R, et al. Impact of referral center pathology review on diagnosis and management of patients with appendiceal neoplasms. *Arch Pathol Lab Med*. 2020;144:764–768.
135. Kolla BC, Petersen A, Chengappa M, et al. Impact of adjuvant chemotherapy on outcomes in appendiceal cancer. *Cancer Med*. 2020;9:3400–3406.
136. Matsui S, Murata K, Fukunaga Y, et al. Analysis of clinicopathological characteristics of appendiceal tumors in Japan: a multicenter collaborative retrospective clinical study—a Japanese nationwide survey. *Dis Colon Rectum*. 2020;63:1403–1410.
137. Mo S, Zhou Z, Ying Z, et al. Epidemiology of and prognostic factors for appendiceal carcinomas: a retrospective, population-based study. *Int J Colorectal Dis*. 2019;34:1915–1924.
138. Shannon AB, Goldberg D, Song Y, et al. Predictors of lymph node metastases in patients with mucinous appendiceal adenocarcinoma. *J Surg Oncol*. 2020;122:399–406.
139. Lu P, Fields AC, Meyerhardt JA, et al. Systemic chemotherapy and survival in patients with metastatic low-grade appendiceal mucinous adenocarcinoma. *J Surg Oncol*. 2019;120:446–451.
140. Wang G, Li Q, Chen W. Chemotherapy in the treatment of different histological types of appendiceal cancers: a SEER based study. *BMC Cancer*. 2021;21:778.
141. Kowalsky SJ, Nassour I, AlMasri S, et al. Omission of right hemicolectomy may be safe for some appendiceal goblet cell adenocarcinomas: a survival analysis of the National Cancer Database. *Ann Surg Oncol*. 2021;28:8916–8925.
142. Zakka K, Williamson S, Jiang R, et al. Is adjuvant chemotherapy beneficial for stage II-III goblet cell carcinoid/goblet cell adenocarcinoma of the appendix? *Surg Oncol*. 2021;36:120–129.
143. Shyu S, Choudry H, Hall L, et al. Clinicopathological analysis of appendiceal goblet cell adenocarcinoma with peritoneal metastasis: World Health Organization grade predicts survival following cytoreductive surgery with intraperitoneal chemotherapy. *Histopathology*. 2020;77:798–809.
144. Foster JM, Gupta PK, Carreau JH, et al. Right hemicolectomy is not routinely indicated in pseudomyxoma peritonei. *Am Surg*. 2012;78:171–177.
145. González-Moreno S, Sugarbaker PH. Right hemicolectomy does not confer a survival advantage in patients with mucinous carcinoma of the appendix and peritoneal seeding. *Br J Surg*. 2004;91:304–311.
146. Sugarbaker PH. When and when not to perform a right colon resection with mucinous appendiceal neoplasms. *Ann Surg Oncol*. 2017;24:729–732.
147. Turaga KK, Pappas S, Gamblin TC. Right hemicolectomy for mucinous adenocarcinoma of the appendix: just right or too much? *Ann Surg Oncol*. 2013;20:1063–1067.
148. Sugarbaker PH. Cytoreductive surgery and perioperative intraperitoneal chemotherapy: a new standard of care for appendiceal mucinous tumors with peritoneal dissemination. *Clin Colon Rectal Surg*. 2005;18:204–214.
149. Sugarbaker PH, Bijelic L. The porta hepatis as a site of recurrence of mucinous appendiceal neoplasms treated by cytoreductive surgery and perioperative intraperitoneal chemotherapy. *Tumori*. 2008;94:694–700.
150. Votanopoulos KI, Bartlett D, Moran B, et al. PCI is not predictive of survival after complete CRS/HIPEC in peritoneal dissemination from high-grade appendiceal primaries. *Ann Surg Oncol*. 2018;25:674–678.
151. Abdel-Rahman O. Impact of cytoreductive surgery on outcomes of metastatic appendiceal carcinoma: a real-world, population-based study. *J Comp Eff Res*. 2020;9:431–439.
152. Bhatt A, Yonemura Y, Benzerdjeb N, et al. Pathological assessment of cytoreductive surgery specimens and its unexplored

Copyright © The American Society of Colon & Rectal Surgeons, Inc. Unauthorized reproduction of this article is prohibited.

prognostic potential—a prospective multi-centric study. *Eur J Surg Oncol*. 2019;45:2398–2404.
153. Ma R, Lu D, Wang B, et al. Complete cytoreductive surgery vs. debulking surgery for pseudomyxoma peritonei of appendiceal origin: a propensity score-matched study based on a single-center experience. *Eur J Surg Oncol*. 2021;47:2369–2376.
154. Munoz-Zuluaga CA, King MC, Ledakis P, et al. Systemic chemotherapy before cytoreductive surgery and hyperthermic intraperitoneal chemotherapy (CRS/HIPEC) in patients with high-grade mucinous carcinoma peritonei of appendiceal origin. *Eur J Surg Oncol*. 2019;45:1598–1606.
155. Tabrizian P, Jibara G, Shrager B, et al. Outcomes for cytoreductive surgery and hyperthermic intraperitoneal chemotherapy in the elderly. *Surg Oncol*. 2013;22:184–189.
156. Lee RM, Gamboa AC, Turgeon MK, et al. A novel preoperative risk score to optimize patient selection for performing concomitant liver resection with cytoreductive surgery/HIPEC. *J Surg Oncol*. 2021;123:187–195.
157. Sabesan A, Felder S, Feuerlein S, et al. Preoperative radiographic assessment predicts incomplete cytoreduction in patients with low grade mucinous adenocarcinoma of the appendix. *Ann Surg Oncol*. 2020;27:165–170.
158. Esquivel J, Garcia SS, Hicken W, Seibel J, Shekitka K, Trout R. Evaluation of a new staging classification and a Peritoneal Surface Disease Severity Score (PSDSS) in 229 patients with mucinous appendiceal neoplasms with or without peritoneal dissemination. *J Surg Oncol*. 2014;110:656–660.
159. Jacquet P, Sugarbaker PH. Clinical research methodologies in diagnosis and staging of patients with peritoneal carcinomatosis. *Cancer Treat Res*. 1996;82:359–374.
160. Yoon W, Alame A, Berri R. Peritoneal Surface Disease Severity Score as a predictor of resectability in the treatment of peritoneal surface malignancies. *Am J Surg*. 2014;207:403–407; discussion 406.
161. Barrak D, Desale S, Yoon JJ, et al. Appendiceal tumors with glandular and neuroendocrine features exhibiting peritoneal metastases—critical evaluation of outcome following cytoreductive surgery with perioperative chemotherapy. *Eur J Surg Oncol*. 2021;47:1278–1285.
162. Byrne RM, Gilbert EW, Dewey EN, et al. Who undergoes cytoreductive surgery and perioperative intraperitoneal chemotherapy for appendiceal cancer? An analysis of the National Cancer Database. *J Surg Res*. 2019;238:198–206.
163. Chen JC, Beal EW, Hays J, Pawlik TM, Abdel-Misih S, Cloyd JM. Outcomes of neoadjuvant chemotherapy before CRS-HIPEC for patients with appendiceal cancer. *J Surg Oncol*. 2020;122:388–398.
164. van Eden WJ, Kok NFM, Snaebjornsson P, et al. Factors influencing long-term survival after cytoreductive surgery and hyperthermic intraperitoneal chemotherapy for pseudomyxoma peritonei originating from appendiceal neoplasms. *BJS Open*. 2019;3:376–386.
165. Kong JC, Flood MP, Guerra GR, et al. Appendiceal pseudomyxoma peritonei: predictors of recurrence and iterative surgery. *Colorectal Dis*. 2021;23:2368–2375.
166. Matar A, Altoukhi K, Tse A, Sohn J, Alzahrani N, Morris DL. Second-look surgery detects low volume recurrent disease following cytoreductive surgery for peritoneal carcinomatosis. *Anticancer Res*. 2022;42:1001–1006.
167. Sutton PA, O'Dwyer ST, Barriuso J, et al. Indications and outcomes for repeat cytoreductive surgery and heated intraperitoneal chemotherapy in peritoneal surface malignancy. *Surg Oncol*. 2021;38:101572.
168. Karpes JB, Lansom JD, Alshahrani M, et al. Repeat cytoreductive surgery with or without intraperitoneal chemotherapy for recurrent epithelial appendiceal neoplasms. *BJS Open*. 2020;4:478–485.
169. Levinsky NC, Morris MC, Wima K, et al. Should we be doing cytoreductive surgery with HIPEC for signet ring cell appendiceal adenocarcinoma? a study from the US HIPEC collaborative. *J Gastrointest Surg*. 2020;24:155–164.
170. Mehta AM, Bignell MB, Alves S, et al. Risk of ovarian involvement in advanced colorectal or appendiceal tumors involving the peritoneum. *Dis Colon Rectum*. 2017;60:691–696.
171. Evers DJ, Verwaal VJ. Indication for oophorectomy during cytoreduction for intraperitoneal metastatic spread of colorectal or appendiceal origin. *Br J Surg*. 2011;98:287–292.
172. Madonia D, Graf W, Ghanipour L. The incidence and prognostic importance of ovarian involvement in patients with peritoneal metastasis undergoing CRS-HIPEC. *Eur J Surg Oncol*. 2022;48:666–671.
173. Zih FS, Wong-Chong N, Hummel C, et al. Mucinous tumor of the appendix with limited peritoneal spread: is there a role for expectant observation? *Ann Surg Oncol*. 2014;21:225–231.
174. Pai RK, Beck AH, Norton JA, Longacre TA. Appendiceal mucinous neoplasms: clinicopathologic study of 116 cases with analysis of factors predicting recurrence. *Am J Surg Pathol*. 2009;33:1425–1439.
175. Yantiss RK, Shia J, Klimstra DS, Hahn HP, Odze RD, Misdraji J. Prognostic significance of localized extra-appendiceal mucin deposition in appendiceal mucinous neoplasms. *Am J Surg Pathol*. 2009;33:248–255.
176. Verwaal VJ, van Ruth S, de Bree E, et al. Randomized trial of cytoreduction and hyperthermic intraperitoneal chemotherapy versus systemic chemotherapy and palliative surgery in patients with peritoneal carcinomatosis of colorectal cancer. *J Clin Oncol*. 2003;21:3737–3743.
177. Verwaal VJ, Bruin S, Boot H, van Slooten G, van Tinteren H. 8-year follow-up of randomized trial: cytoreduction and hyperthermic intraperitoneal chemotherapy versus systemic chemotherapy in patients with peritoneal carcinomatosis of colorectal cancer. *Ann Surg Oncol*. 2008;15:2426–2432.
178. Elias D, Glehen O, Pocard M, et al; Association Française de Chirurgie. A comparative study of complete cytoreductive surgery plus intraperitoneal chemotherapy to treat peritoneal dissemination from colon, rectum, small bowel, and nonpseudomyxoma appendix. *Ann Surg*. 2010;251:896–901.
179. Yan TD, Links M, Xu ZY, Kam PC, Glenn D, Morris DL. Cytoreductive surgery and perioperative intraperitoneal chemotherapy for pseudomyxoma peritonei from appendiceal mucinous neoplasms. *Br J Surg*. 2006;93:1270–1276.
180. Chua TC, Martin S, Saxena A, et al. Evaluation of the cost-effectiveness of cytoreductive surgery and hyperthermic intraperitoneal chemotherapy (peritonectomy) at the St George Hospital peritoneal surface malignancy program. *Ann Surg*. 2010;251:323–329.
181. El Halabi H, Gushchin V, Francis J, et al. The role of cytoreductive surgery and heated intraperitoneal chemotherapy (CRS/

Copyright © The American Society of Colon & Rectal Surgeons, Inc. Unauthorized reproduction of this article is prohibited.

HIPEC) in patients with high-grade appendiceal carcinoma and extensive peritoneal carcinomatosis. *Ann Surg Oncol*. 2012;19:110–114.
182. Polanco PM, Ding Y, Knox JM, et al. Outcomes of cytoreductive surgery and hyperthermic intraperitoneal chemoperfusion in patients with high-grade, high-volume disseminated mucinous appendiceal neoplasms. *Ann Surg Oncol*. 2016;23:382–390.
183. Elias D, Honoré C, Ciuchendéa R, et al. Peritoneal pseudomyxoma: results of a systematic policy of complete cytoreductive surgery and hyperthermic intraperitoneal chemotherapy. *Br J Surg*. 2008;95:1164–1171.
184. McDonald JR, O'Dwyer ST, Rout S, et al. Classification of and cytoreductive surgery for low-grade appendiceal mucinous neoplasms. *Br J Surg*. 2012;99:987–992.
185. Mehta A, Mittal R, Chandrakumaran K, et al. Peritoneal involvement is more common than nodal involvement in patients with high-grade appendix tumors who are undergoing prophylactic cytoreductive surgery and hyperthermic intraperitoneal chemotherapy. *Dis Colon Rectum*. 2017;60:1155–1161.
186. Youssef H, Newman C, Chandrakumaran K, Mohamed F, Cecil TD, Moran BJ. Operative findings, early complications, and long-term survival in 456 patients with pseudomyxoma peritonei syndrome of appendiceal origin. *Dis Colon Rectum*. 2011;54:293–299.
187. Quénet F, Elias D, Roca L, et al; UNICANCER-GI Group and BIG Renape Group. Cytoreductive surgery plus hyperthermic intraperitoneal chemotherapy versus cytoreductive surgery alone for colorectal peritoneal metastases (PRODIGE 7): a multicentre, randomised, open-label, phase 3 trial. *Lancet Oncol*. 2021;22:256–266.
188. Levine EA, Votanopoulos KI, Shen P, et al. A multicenter randomized trial to evaluate hematologic toxicities after hyperthermic intraperitoneal chemotherapy with oxaliplatin or mitomycin in patients with appendiceal tumors. *J Am Coll Surg*. 2018;226:434–443. Published correction appears in J Am Coll Surg. 2018;227:633.
189. Zhang X, Wu Q, Wei M, Deng X, Gu C, Wang Z. Oxaliplatin versus mitomycin C in HIPEC for peritoneal metastasis from colorectal cancer: a systematic review and meta-analysis of comparative studies. *Int J Colorectal Dis*. 2020;35:1831–1839.
190. Prada-Villaverde A, Esquivel J, Lowy AM, et al. The American Society of Peritoneal Surface Malignancies evaluation of HIPEC with mitomycin C versus oxaliplatin in 539 patients with colon cancer undergoing a complete cytoreductive surgery. *J Surg Oncol*. 2014;110:779–785.
191. Hassan S, Dritsas S, O'Dwyer ST, et al; other members of the Colorectal and Peritoneal Oncology Group. Open versus Closed technique for administration of heated intraperitoneal chemotherapy (HIPEC): morbidity and mortality outcomes from a high-volume centre. *Eur J Surg Oncol*. 2023;49:106924.
192. Culliford AT IV, Brooks AD, Sharma S, et al. Surgical debulking and intraperitoneal chemotherapy for established peritoneal metastases from colon and appendix cancer. *Ann Surg Oncol*. 2001;8:787–795.
193. Fajardo AD, Tan B, Reddy R, Fleshman J. Delayed repeated intraperitoneal chemotherapy after cytoreductive surgery for colorectal and appendiceal carcinomatosis. *Dis Colon Rectum*. 2012;55:1044–1052.
194. Huang Y, Alzahrani NA, Liauw W, Soudy H, Alzahrani AM, Morris DL. Early postoperative intraperitoneal chemotherapy is associated with survival benefit for appendiceal adenocarcinoma with peritoneal dissemination. *Eur J Surg Oncol*. 2017;43:2292–2298.
195. Lam JY, McConnell YJ, Rivard JD, Temple WJ, Mack LA. Hyperthermic intraperitoneal chemotherapy + early postoperative intraperitoneal chemotherapy versus hyperthermic intraperitoneal chemotherapy alone: assessment of survival outcomes for colorectal and high-grade appendiceal peritoneal carcinomatosis. *Am J Surg*. 2015;210:424–430.
196. Huang Y, Alzahrani NA, Liauw W, Traiki TB, Morris DL. Early postoperative intraperitoneal chemotherapy for low-grade appendiceal mucinous neoplasms with pseudomyxoma peritonei: is it beneficial? *Ann Surg Oncol*. 2017;24:176–183.
197. Wagner PL, Jones D, Aronova A, et al. Multi-cycle early postoperative intraperitoneal chemotherapy (EPIC) following cytoreductive surgery for appendiceal neoplasms with isolated peritoneal metastasis. *Ann Surg Oncol*. 2010;17:S86.
198. Lemoine L, Sugarbaker P, Van der Speeten K. Drugs, doses, and durations of intraperitoneal chemotherapy: standardising HIPEC and EPIC for colorectal, appendiceal, gastric, ovarian peritoneal surface malignancies and peritoneal mesothelioma. *Int J Hyperthermia*. 2017;33:582–592.
199. Wagner PL, Jones D, Aronova A, et al. Early postoperative intraperitoneal chemotherapy following cytoreductive surgery for appendiceal mucinous neoplasms with isolated peritoneal metastasis. *Dis Colon Rectum*. 2012;55:407–415.
200. Lieu CH, Lambert LA, Wolff RA, et al. Systemic chemotherapy and surgical cytoreduction for poorly differentiated and signet ring cell adenocarcinomas of the appendix. *Ann Oncol*. 2012;23:652–658.
201. Shapiro JF, Chase JL, Wolff RA, et al. Modern systemic chemotherapy in surgically unresectable neoplasms of appendiceal origin: a single-institution experience. *Cancer*. 2010;116:316–322.
202. Blackham AU, Swett K, Eng C, et al. Perioperative systemic chemotherapy for appendiceal mucinous carcinoma peritonei treated with cytoreductive surgery and hyperthermic intraperitoneal chemotherapy. *J Surg Oncol*. 2014;109:740–745.
203. Sugarbaker PH, Bijelic L, Chang D, Yoo D. Neoadjuvant FOLFOX chemotherapy in 34 consecutive patients with mucinous peritoneal carcinomatosis of appendiceal origin. *J Surg Oncol*. 2010;102:576–581.
204. Milovanov V, Sardi A, Ledakis P, et al. Systemic chemotherapy (SC) before cytoreductive surgery and hyperthermic intraperitoneal chemotherapy (CRS/HIPEC) in patients with peritoneal mucinous carcinomatosis of appendiceal origin (PMCA). *Eur J Surg Oncol*. 2015;41:707–712.
205. Bijelic L, Kumar AS, Stuart OA, Sugarbaker PH. Systemic chemotherapy prior to cytoreductive surgery and HIPEC for carcinomatosis from appendix cancer: impact on perioperative outcomes and short-term survival. *Gastroenterol Res Pract*. 2012;2012:163284.
206. Asare EA, Compton CC, Hanna NN, et al. The impact of stage, grade, and mucinous histology on the efficacy of systemic chemotherapy in adenocarcinomas of the appendix: analysis of the National Cancer Data Base. *Cancer*. 2016;122:213–221.
207. Farquharson AL, Pranesh N, Witham G, et al. A phase II study evaluating the use of concurrent mitomycin C and capecitabine

Copyright © The American Society of Colon & Rectal Surgeons, Inc. Unauthorized reproduction of this article is prohibited.

in patients with advanced unresectable pseudomyxoma peritonei. *Br J Cancer*. 2008;99:591–596.
208. Solass W, Kerb R, Mürdter T, et al. Intraperitoneal chemotherapy of peritoneal carcinomatosis using pressurized aerosol as an alternative to liquid solution: first evidence for efficacy. *Ann Surg Oncol*. 2014;21:553–559.
209. Somashekhar SP, Abba J, Sgarbura O, et al; PIPAC Study Group. Assessment of treatment response after pressurized intraperitoneal aerosol chemotherapy (PIPAC) for appendiceal peritoneal metastases. *Cancers (Basel)*. 2022;14:4998.
210. Alyami M, Hübner M, Grass F, et al. Pressurised intraperitoneal aerosol chemotherapy: rationale, evidence, and potential indications. *Lancet Oncol*. 2019;20:e368–e377.
211. Grass F, Vuagniaux A, Teixeira-Farinha H, Lehmann K, Demartines N, Hübner M. Systematic review of pressurized intraperitoneal aerosol chemotherapy for the treatment of advanced peritoneal carcinomatosis. *Br J Surg*. 2017;104:669–678.
212. Lurvink RJ, Rovers KP, Nienhuijs SW, Creemers GJ, Burger JWA, de Hingh IHJ. Pressurized intraperitoneal aerosol chemotherapy with oxaliplatin (PIPAC-OX) in patients with colorectal peritoneal metastases—a systematic review. *J Gastrointest Oncol*. 2021;12(suppl 1):S242–S258.
213. Nowacki M, Alyami M, Villeneuve L, et al. Multicenter comprehensive methodological and technical analysis of 832 pressurized intraperitoneal aerosol chemotherapy (PIPAC) interventions performed in 349 patients for peritoneal carcinomatosis treatment: an international survey study. *Eur J Surg Oncol*. 2018;44:991–996.
214. Kim G, Tan HL, Sundar R, et al. PIPAC-OX: a phase I study of oxaliplatin-based pressurized intraperitoneal aerosol chemotherapy in patients with peritoneal metastases. *Clin Cancer Res*. 2021;27:1875–1881.
215. Kurtz F, Struller F, Horvath P, et al. Feasibility, safety, and efficacy of pressurized intraperitoneal aerosol chemotherapy (PIPAC) for peritoneal metastasis: a registry study. *Gastroenterol Res Pract*. 2018;2018:2743985.
216. Frøysnes IS, Andersson Y, Larsen SG, et al. ImmunoPeCa trial: long-term outcome following intraperitoneal MOC31PE immunotoxin treatment in colorectal peritoneal metastasis. *Eur J Surg Oncol*. 2021;47:134–138.
217. Frøysnes IS, Andersson Y, Larsen SG, et al. Novel treatment with intraperitoneal MOC31PE immunotoxin in colorectal peritoneal metastasis: results from the ImmunoPeCa phase 1 trial. *Ann Surg Oncol*. 2017;24:1916–1922.
218. Feng J, Li K, Liu G, Feng Y, Shi H, Zhang X. Precision hyperthermia-induced miRNA-409-3p upregulation inhibits migration, invasion, and EMT of gastric cancer cells by targeting KLF17. *Biochem Biophys Res Commun*. 2021;549:113–119.
219. Sugarbaker PH, Stuart OA. Pharmacokinetics of the intraperitoneal nanoparticle pegylated liposomal doxorubicin in patients with peritoneal metastases. *Eur J Surg Oncol*. 2021;47:108–114.
220. Wu HT, Peng KW, Ji ZH, et al. Cytoreductive surgery plus hyperthermic intraperitoneal chemotherapy with lobaplatin and docetaxel to treat synchronous peritoneal carcinomatosis from gastric cancer: results from a Chinese center. *Eur J Surg Oncol*. 2016;42:1024–1034.
221. Wu HT, Yang XJ, Huang CQ, et al. Cytoreductive surgery plus hyperthermic intraperitoneal chemotherapy with lobaplatin and docetaxel improves survival for patients with peritoneal carcinomatosis from abdominal and pelvic malignancies. *World J Surg Oncol*. 2016;14:246.
222. Morton DL, Ollila DW, Hsueh EC, Essner R, Gupta RK. Cytoreductive surgery and adjuvant immunotherapy: a new management paradigm for metastatic melanoma. *CA Cancer J Clin*. 1999;49:101–16, 65.

Copyright © The American Society of Colon & Rectal Surgeons, Inc. Unauthorized reproduction of this article is prohibited.